

## STAB WITH SICKLE IMPACTED IN THE VAULT OF SKULL AN UN-USUAL FINDING ON IMAGING

Nizamuddin Memon, Aftab A. Qureshi , Muneer A. Junjeo,  
A. Sattar Memon and Bikha Ram Devrajani

### ABSTRACT

We report a case with an unusual finding in which a part of sickle was seen impacted in the skull after causing the fracture of right parietal bone. This young injured person was brought in emergency department with metallic foreign body in vault of skull as a result of assault while he was cutting grass in the field.

He was operated on the next day and the foreign body was removed. His condition was improved and after ten days he was discharged with no neurological deficit.

**KEY WORDS:** *Injury. Imaging. Foreign Body. Neurosurgery.*

### CASE REPORT

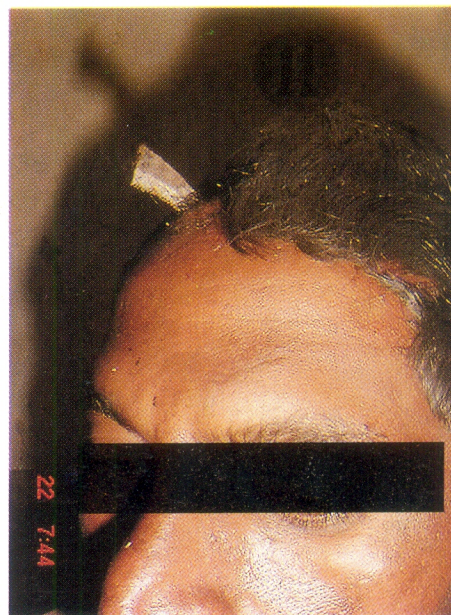A 27 years old male patient was brought into neuroemergency department of Liaquat University Hospital, Hyderabad after a stab injury to right parietal region with the history of assault. He was conscious, without history of vomiting or ear nose throat bleeding. He was advised X-rays for skull; AP and lateral views along with other routine investigations. The X-ray films showed a curved metallic foreign body shadow extending into right parietal region in side the vault which was about the half of its length (**Fig I-III**). The sickle was removed and then C.T Scan Brain was suggested after 6 days to see intracranial lesion due to injury. Multiple axial scans of 10mm thickness were taken from orbito-meatal line which revealed discontinuity of the vault of skull in the right parietal bone anteriorly. A small rounded area of air density was seen along the inner table in the right parietal region, probably due to injury. The brain parenchyma was congested at the site of injury in right cerebral hemisphere. No evidence of intra cranial heamatoma, or mid line shift was seen. The ventricles were normal (**FIG IV**).

#### The operative note:

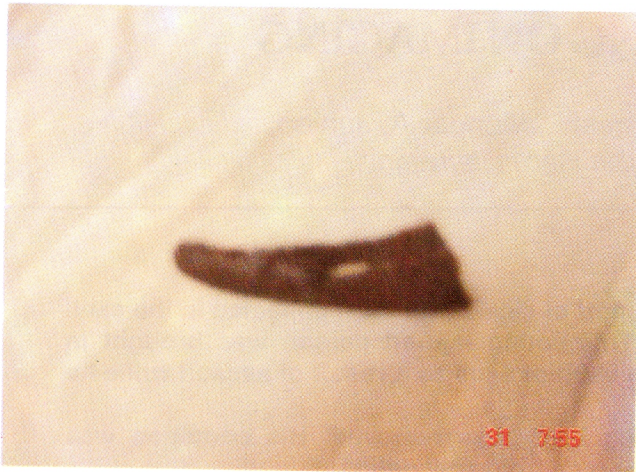The operation was performed under general anaesthesia. The oblique incision was given near foreign body, wound and washed periosteum were retracted. A burhole was made on the right side of the foreign body and then small craniectomy was done around the foreign body to remove it. Foreign body

was penetrating the dura. Durameter was washed and repaired with silk 2/0. After doing other steps the wound was closed in layers. The patient was discharged after ten days without any neurological symptoms / deficit. The CT Scan was done on last day and patient returned home. After two days, he returned with history of fits, weakness and pain in left sided limbs. He stayed for another week in the ward, where complaints of left sided upper and lower limbs were recovered. Patient was then discharged on his wish still with the complaint of fits off and on.

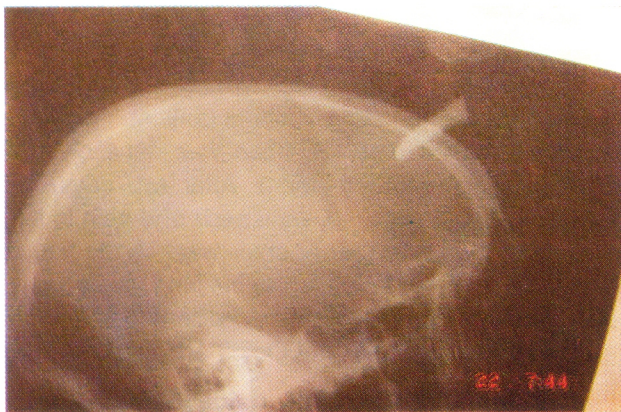
**Figure-I: Foreign Body inside the skull**



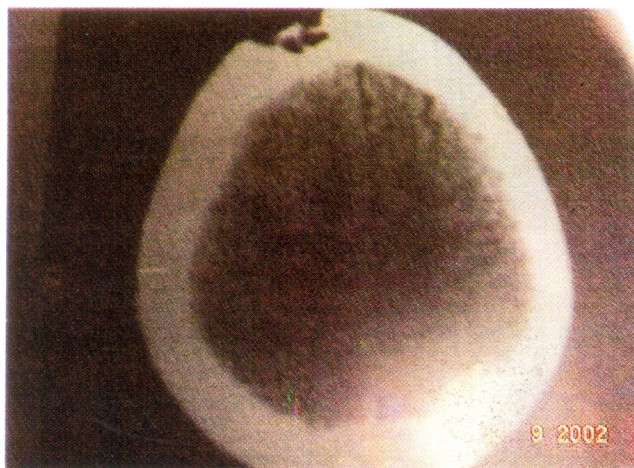**Figure-II: Foreign Body removed after operation**



**Figure-III:  
Foreign body is seen in right parietal region.**



**Figure-IV:  
Discontinuity of the vault of skull in right parietal  
region seen with area of air DENSITY**



## DISCUSSION

Head trauma has been reported as the third leading cause of death in general population<sup>1</sup> and particularly it is the leading cause in individuals under age of 30 years. It may be due to road traffic accidents falls, assault, recreational and sports injuries. Below the age of 65 years trauma causes loss of more years of potential life than neoplasm or cardiac disease. An algorithm for radiologic evaluation of head injury patients was made by grouping – low, moderate and high risk, which includes the penetrating skull injuries or palpable depressed fracture<sup>2</sup>. Depressed and basilar skull fractures are better seen with C.T scan than routine skull films<sup>3</sup>. It is also useful in the examination of multiple injuries. It shows the commonest traumatic lesions i.e. linear and depressed fractures, foreign body of metallic density, pneumocranium and pneumocephalus, contusion, haematoma with oedema, acute subdural haematoma, chronic subdural haematoma with re-bleeding and extra dural haematoma. In traumatic cases, CT must be the first choice modality in all patients with sudden neurological deficit. It provides the initial most useful information on the presence or absence of a surgically manageable condition. But since CT Scanner facility is not available every where and specially close to the emergency unit so in routine, conventional radiography of skull is advised. It however, gives less information. Linear, comminuted and depressed fractures may be diagnosed, however in various series less than 9% of skull radiographs have showed fracture<sup>4,5</sup>. More importantly there is little relationship between calvarial and intra cranial injuries. A study of multi disciplinary panel reviewed the findings in 22,958 patients, fractures were found in 3% with 9% of intracranial injuries and intracranial injuries were found in 0.6% with 51% did not have fracture<sup>2</sup>.

CT Scan is sensitive in detecting the smaller amounts of intracranial air as compared with skull x-ray and much better than skull x-ray in anatomical localization of metallic foreign bodies.

Several studies suggest that MRI is not only more sensitive at detecting intracerebral trauma but also demonstrates lesions earlier. However, MRI is less available than CT at this time, particularly in the trauma centers. The advent of multi slice spiral CT also have much improved contrast and spatial resolution than conventional CT Scanners<sup>6</sup>.

## REFERENCES

1. Kelly AB, Zimmerman RD, Snow RB. Head trauma; comparison of CT and MRI experience in 100 patients. AJNR. 1988; 9: 699-708.

2. Master SJ, Clean PM, Arcarese JS et al. Skull X-ray examination after head trauma: recommendations by a multidisciplinary panel and validation study. *N Engl J Med.* 1987; 316: 84-91.
3. Dublin AB, French BN, Rennick JM. Computed Tomography in head trauma. *Radiology.* 1977; 122: 365-369.
4. Bell RS, Loop JW. The utility and futility of radiographic skull examination for trauma. *N Engl J Med.* 1971; 284: 236-239.
5. Royal College of Radiologists. A study of utilization of skull radiology in 9 accident and emergency units in the UK. *Lancet.* 1980; 2: 1234-1237.
6. Jermy WR. Youngs skeletal trauma regional. David Sutton. 2003; pp 1389-90.

.....  
**Correspondence:**

Dr. Nizamuddin Memon  
Associate Professor, Department of Radiology & Imaging  
Liaquat University of Medical & Health Sciences  
Jamshoro, Pakistan.

