

INDUCTION OF RHABDOMYOSARCOMA IN ALBINO RATS BY SUB CUTANEOUS INJECTIONS OF VARIOUS CARCINOGENS AND CO-CARCINOGENS

Abdul Latif Soomro, N A Jafarey and Nasreen Junejo

ABSTRACT

OBJECTIVE: To study the effects of a crude water extract of *Fagonia Arabica*, a malignant tumour (Rhabdomyosarcoma) was produced in albino rats with the help of a carcinogen (20-Methylcholanthrene) and co-carcinogens including Qawam (tobacco extract).

DESIGN: An experimental study.

SETTING: Basic Medical Sciences Institute (BMSI), Jinnah Postgraduate Medical Centre (JPMC), Karachi Pakistan.

METHODS: Thirty Albino rats were given subcutaneous injections of 75 micro grams of 20-Methylcholanthrene in 0.5 ml of olive oil twice a day for two weeks. Various carcinogens and co-carcinogens like tobacco tar, tobacco paste (Qawam), euphorbia plant extract and croton oil were also applied at different occasions locally on the right side of the back of these animals after shaving about 6 square cms area. This was continued till thirty-first week.

RESULTS: At the end of fortieth week, a palpable nodule firm in consistency was noticeable in twenty-six out of thirty animals initially taken for this purpose. Histological examination of biopsy in two animals confirmed malignancy that on special staining showed striations and a diagnosis of Rhabdomyosarcoma was made.

CONCLUSION: An animal model of producing Rhabdomyosarcoma in albino rats has been described. This model can be used for studying the anti-tumour effects of various plant extracts.

KEY WORDS: *Rhabdomyosarcoma. Carcinogen. Rats.*

INTRODUCTION

Experimental animals like rats, guinea pigs etc. have been used for the induction of various tumours for testing the effect of various agents on these tumours. In order to study the effect of a crude water extract of *Fagonia indica*¹, a Rhabdomyosarcoma was successfully induced in albino rats.

MATERIAL AND METHODS

This experimental study was conducted in 1978 at Basic Medical Sciences Institute (BMSI), Jinnah Postgraduate Medical Centre (JPMC), Karachi. Thirty (15 male and 15 female) Albino rats of Sprague Dawly strain were used. All the rats were 12 weeks of age, weighed between 120 to 200gms and were reared in the animal house of JPMC.

Carcinogen and co-carcinogens used:

The tumour was produced by using a combination of 20-methylcholanthrene, tobacco tar, qawam, croton oil, crude water extract of euphorbia, acetone, olive oil, cortisone and hair remover cream. Ether was used for anesthesia. The method of the preparation of the above agents is described below:

20-methylcholanthrene and bees wax carcinogen mixture: First, 450 mgs of bees wax was melted in a brown wide mouthed glass bottle in a water bath at 65°C. Then 150mgs of 20-methylcholanthrene (Bios Laboratories Incorporated New York, USA), was added to the melted bees wax and mixed thoroughly by means of a thin glass rod. It turned into a yellow thin pasty substance, which solidified on room temperature and was melted every time before use.

Euphorbia extract: Euphorbia tirucelli plant is found in the hilly tracts around Jamshoro, Sindh. Whole plants including its branches were cut into small pieces. The pieces weighing about 500gms were taken into a mixed in a mortar with sufficient quantity of water not exceeding 100mls. The plant pieces were crushed with the help of a pestle. The contents were filtered through muslin cloth and stored in a brown bottle. Water was added to make a 100ml solution.

Qawam and euphorbia extract paste: 30 gms of saturated qawam (a local preparation of tobacco paste, manufactured by Aziz and Sons, Karachi) were mixed in 30 mls of euphorbia water extract and mixed thoroughly in a beaker with the help of a glass rod to make it a thin paste.

20-methylcholanthrene, bees wax preparation, croton oil and tobacco tar paste: 450 mgs of the 20-methylcholanthrene bees wax preparation, 5cc croton oil (Tibi Markaz, Karachi), and 200 gms of tobacco tar (collected by scrapping the inside of the neck of the pot in which tobacco is burned. The tar was collected every week before application). The above were added and mixed thoroughly to make a thin paste.

Qawam and cortisone paste: 30 gms of qawam (manufactured by Aziz and Sons, Karachi) plus 30 mgs of cortisone (In amorphous form manufactured by Ciba Giegy) and 30 ml of distilled water were mixed to make a thin pasty substance. It was prepared fresh for each application.

Qawam, cortisone and 20-methylcholanthrene paste: 3 mgs of 20-methylcholanthrene were added to the above described paste.

An approximately 6 square cm area of the backs of thirty animals was cleared of hair by using a hair remover (Anne French). This area was used for the local application of various pastes described above. This method is similar to that described by Frie².

As no tumour was observed by the end of the fifteenth week, it was decided to give a subcutaneous injection of 20-methylcholanthrene in the experimental area. In the 16th and 17th weeks of the experiment, 75 micrograms of 20-methylcholanthrene mixed in 0.5 ml of Olive oil (Hersteller P. Sasso e. FIGLI Oneglia Italy), was given subcutaneously twice a week. Thus four such injections were given subcutaneously in the center of the shaved area during the sixteenth and seventeenth week. In addition to the subcutaneous injection of 20-methylcholanthrene, application of tobacco paste (Qawam) was also continued six times a week. The use of hydrocortisone and 20-methylcholanthrene – qawam paste was discontinued. As no tumour was still observed, intramuscular hydrocortisone injections were added to suppress the immunity by giving 0.5 mgms of hydrocortisone dissolved in 1 ml of distilled water in the thigh muscles six times a week. Qawam application was also continued in the eighteenth week. Only qawam was applied in the nineteenth to the twenty-second weeks. The local application of qawam was, however, continued six times till the end of thirty first week.

During the entire experimental period weekly observations of general condition, weight in grams, drugs used with dosage, applications per week, change at local site, date of appearance of swelling, size of tumour and date of biopsy were recorded. Anything extraordinary observed was noted in a separate column captioned as general remarks.

When the tumour size reached 1.0 cm, the date was recorded and this became the day 0 for the study of *Fagonia* extract in 26 out of 30 animals in which a tumour appeared.

RESULTS

In the 23rd week, one firm swelling of about 0.2 cms diameter was observed in one male animal on palpation of the shaved area. At the end of 31 weeks nodules were noted in 21 out of 30 animals. By the end of 40th week, a tumour was produced in 26 animals (11 males and 15 females). In two animals, a biopsy was performed to confirm that a malignant tumour has appeared. An autopsy was done in all the 26 tumour-bearing animals after they expired or were sacrificed. On gross examination, the tumour appeared as a single firm to hard and spherical mass. A few multilobulated forms were also seen but in no case more than one tumour mass or metastasis was seen. The mean largest diameter of tumour was 8.12 cms while mean weight of tumour was 158.9 gms (Table I). They were grayish pink in colour with a rough uneven surface (Figure I). The cut section showed that the tumour was well demarcated with an apparent capsule. The cut surface showed an interlacing maze of strands extending in all directions and dividing the tumour into incomplete lobules. The surface was grayish white in colour and had a glistening appearance. Some of the tumours showed friable necrotic central areas which at times were cystic. Haemorrhagic areas were also seen in a few cases.

On microscopic examination, sections revealed a tumour composed of spindle to spherical cells mostly arranged in a loose fashion. At places the cells showed bundle formation and these bundles had a wavy arrangement at some places (Figures II and III). Some areas showed sheets of closely packed fibers that were arranged in an interlacing fashion. The loose textured areas consisted of myxomatous tissue containing scanty spindle and stellate shaped nuclei. Numerous congested blood vessels were seen in some sections. Some tumours had ulcerations with sections showing a layer of necrotic tissue on side. The cells varied in shape and size both, ranging from small spindle to the extent of large, polyhedral and foamy cells. The nuclei varied from spindle to oval with darkly staining chromatin in the fiber like cells. No nucleoli were seen in these cells. Where the cells were large and polyhedral, they showed either lightly staining basophilic cytoplasm or abundant deep eosinophilic cytoplasm. In the eosinophilic cells the nuclei were large and irregular resembling the so-called racquet cells or Rhabdomyoblast. The nuclei of

a few large polyhedral cells showed dispersed but condensed chromatin material. Some of the cells showed 1-2 nucleoli. Tumour giant cells were also seen in most of the cases. Three to seven mitotic figures per high power field were seen in the large cells only.

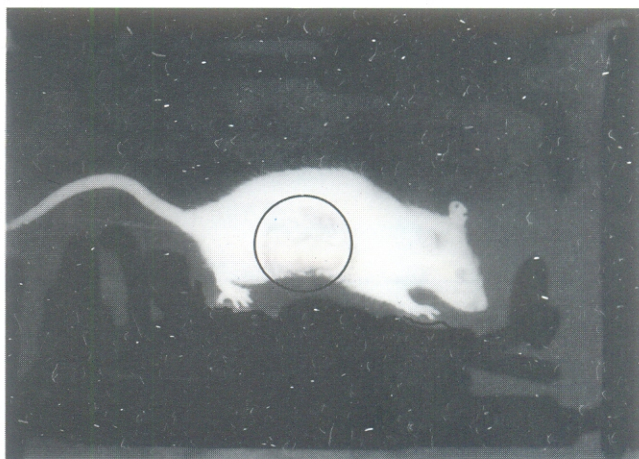Trichrome stained sections showed muscle fibers only which indicated that the tumour was either a Rhabdomyosarcoma or Leiomyosarcoma. Sections of the same cases stained with Phosphotungstic acid haemotoxylin stain showed striations in some of the tumour cells while others had ill defined striations. It was concluded that the tumour was a poorly differentiated Rhabdomyosarcoma.

TABLE I
SHOWING WEIGHT AND SIZE OF TUMOUR IN
ANIMALS OF BOTH SEXES AT AUTOPSY

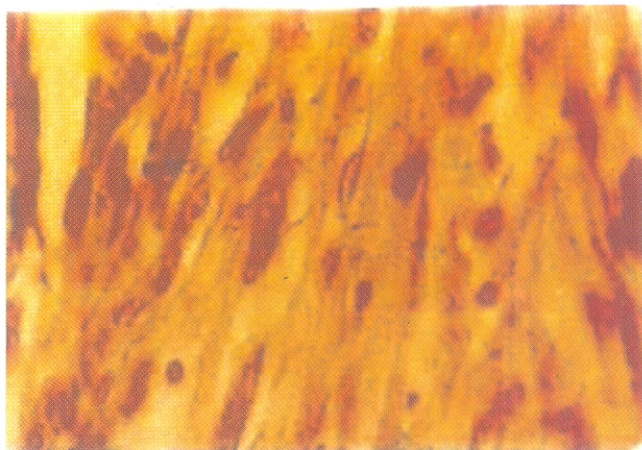
Number	Sex	Weight of tumour (gms)	Largest size of tumour (cms)
2	M	300	9
4	M	25	3
5	M	150	5
6	M	20	4
8	M	200	11
10	M	200	8
11	M	150	7
12	M	300	11
13	M	15	3
14	M	350	11
15	M	250	11
16	F	150	13
17	F	300	10
18	F	50	5
19	F	150	8
20	F	110	10
21	F	250	11
22	F	150	11
23	F	150	11
24	F	100	5
25	F	75	7
26	F	250	11
27	F	120	8
28	F	15	3
29	F	250	9
30	F	50	5

M = Male, F= Female, gms = Grams, cms = Centimeters

Figure I showing tumor on gross examination of rat



Figures II and III showing histopathological features of tumor



DISCUSSION

At present the screening of anti-tumour activity of various plant extracts are done on cell culture lines. Cell culture lines were not available to us in 1978. This is the reason we ventured to produce tumours in rats. Tumour cell lines are still not available. The animal model that has been described here could be used for anti-tumour activity studies of local plants.

REFERENCES

1. Soomro AL, Jafarey NA. Effect of fagonia indica on experimentally produced tumours in Rats. J Pak Med Assoc 2003; 53: 224-25.
2. Frei JV, Ritchie AC. Epidermal carcinogenesis by carcinogen followed by various concentrations of croton oil. J Nat Cancer Inst 1962; 29: 687-97.



AUTHOR AFFILIATION AND CORRESPONDENCE ADDRESS:

Dr. Abdul Latif Soomro (*Corresponding Author*)

Professor, Department of Pathology Liaquat University of Medical & Health Sciences (LUMHS), Jamshoro, Sindh, Pakistan. E-mail: soomroals@hotmail.com

Dr. N A Jafarey

Advisor, Ziauddin Medical University, Karachi, Paksitan.

Dr. Nasreen Junejo

Assistant Professor, Department of Pharmacology LUMHS, Jamshoro, Sindh, Pakistan.