

ULTRASONOGRAPHY OF OVARIAN TUMORS: PREDICTABILITY OF TUMOR TYPE

Nishat Zohra

ABSTRACT

OBJECTIVE: To determine the accuracy of ultrasonography in predicting the tumor type, so that the diagnosis of malignancy can be suggested preoperatively and appropriate treatment planned.

DESIGN: Descriptive study.

SETTING: Department of Gynaecology and Obstetrics, Liaquat University Hospital, Hyderabad, Pakistan from 1996-2000.

PATIENTS AND METHODS: Case records of 87 patients with ovarian tumors were analyzed. All these patients had preoperative ultrasound examination. Ultrasound findings were compared with histopathological findings.

RESULTS: Four patients with false positive diagnosis of ovarian tumor were excluded from this study. Out of 83 cases, 59 were benign and 24 malignant ovarian tumors. Solid component was present in 80% cases of malignant tumors and 20% of malignant tumors were cystic with septations. Solid component was also seen in 27.58% of benign tumors. Unilocular clear cysts were all benign. Dermoid cysts were all diagnosed on ultrasound.

CONCLUSION: Anechoic masses have high probability of being benign and possibility of malignancy increases with the presence of solid component. Sensitivity and specificity for diagnosing malignant tumor can increase with the use of transvaginal color Doppler Ultrasound and magnetic resonance imaging.

KEY WORDS: *Tumor. Ovary. Histopathology. Ultrasound.*

INTRODUCTION

Ovarian malignancy accounts for 25% of all gynecological cancers. Fifty percent of all deaths from cancer of female genital tract are due to ovarian malignancy¹. The reason for poor outcome is the inability to diagnose the disease in early stage. Because of their painless nature and non disturbance of menstrual function these tumors remain occult for a prolonged period. In more than 75% of cases, diagnosis is made when the disease has spread widely². Ideally, disease should be detected in stage 1a, as the 5 year survival rates for women with well differentiated stage1 epithelial tumors is as high as 98% with complete cure after surgery alone³. Various techniques for early detection of ovarian tumors have been explored. Computerized tomography and magnetic resonance imaging (MRI) may detect small volume ovarian cancer but their invasiveness and expense limit their use. Non invasive nature and easy availability of ultrasound makes this a technique of choice for detection and characterization of ovarian tumors⁴. Efficacy of abdominal ultrasound is reported 86.6% in preoperative evaluation and in differentiating

benign from malignant tumors⁵. The most commonly used classification of ovarian tumors is defined by the world health organization⁶. This is morphological classification that attempts to relate the cell type and pattern of the tumor to tissues that are normally present in ovary. The primary tumors are divided into tumors of epithelial origin, sex cord mesenchymal type and tumors of germ cell type. Differential diagnosis of ovarian tumors includes full bladder, pregnant uterus, ectopic pregnancy, pelvic inflammatory disease, appendicitis, fibroids, rectal malignancy and diverticulosis.

Objective of this study was to evaluate the ovarian tumors with respect to echogenic characteristics and histopathology and to determine the accuracy of ultrasonography in predicting the tumor type so that diagnosis of malignancy is suggested preoperatively and appropriate treatment can be planned.

MATERIAL AND METHODS

This study was carried out at obstetrics and gynecology department of Liaquat University Hospital, Hyderabad during the years 1996 – 2000. All patients had preoperative ultrasound examination at

department. Scans were obtained with Hitachi EUB-26 real time scanner. 3.5 MHZ electronic linear array transducer was also used. All patients were operated at Obstetrics and Gynecology department while histopathological examination of tumors was done at pathology department of Liaquat University of Medical and Health Sciences, Jamshoro, Sindh. Tumors were grouped in different categories according to the internal echo architecture on ultrasound scans. First group consisted of completely solid tumors. Second group was of complex tumors containing both solid and cystic areas (Figure I). Third group consisted of cystic tumors. This group was further divided into three categories; anechoic or clear cysts (Figure II), cysts with internal echoes (Figure III) and cysts with septations (Figure IV). Each tumor was analyzed according to histopathology and ultrasound architecture.

FIGURE I: SOLID TUMOR WITH CYSTIC AREAS

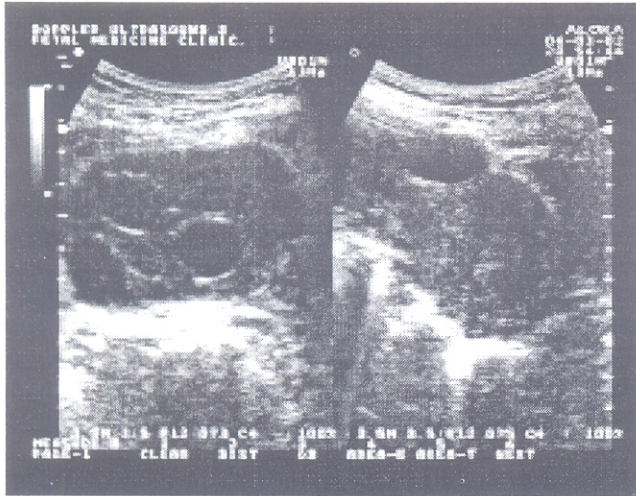


FIGURE II: ANECHOIC CLEAR CYST

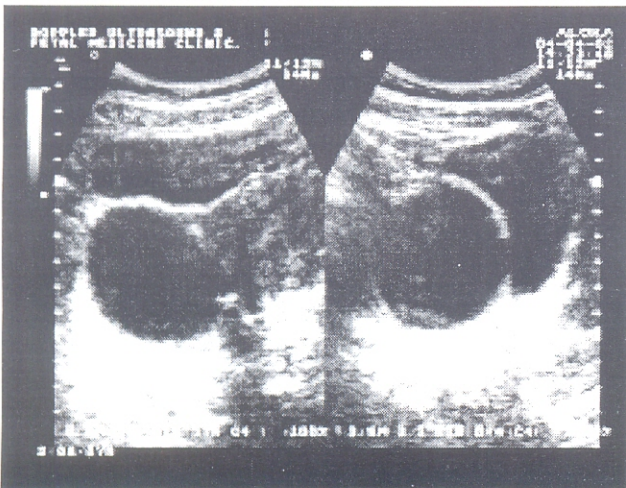


FIGURE III: CYST WITH INTERNAL ECHOES

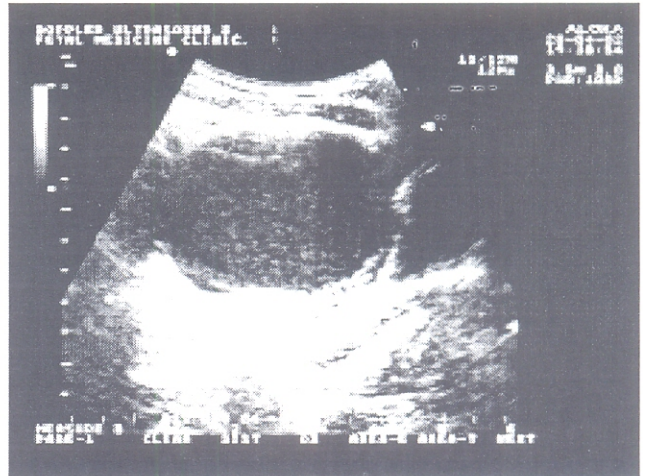
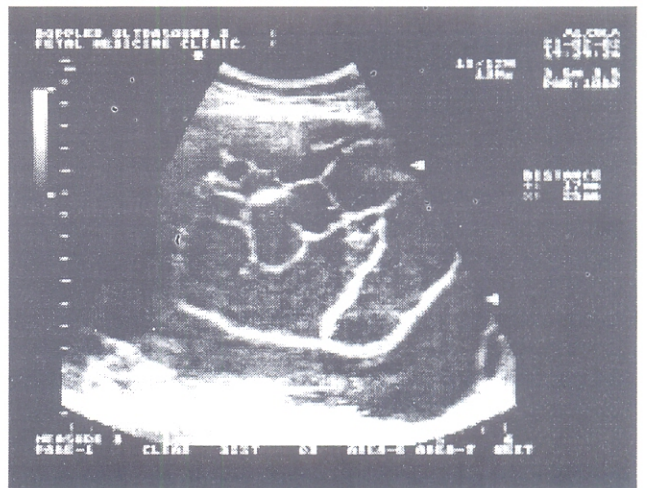


FIGURE IV: CYST WITH SEPTATIONS



RESULTS

In 87 patients, ovarian tumor was diagnosed on ultrasound. False positive diagnosis of an ovarian tumor was made in four cases. Three leiomyomas with degeneration and one hydatid cyst were diagnosed as an ovarian tumor. These patients were excluded. Out of 83 ovarian tumours, 58 tumors were benign and 25 were malignant. Evaluation of echogenic characteristics and histology of each tumor was done (Table I). Majority of the tumors were mucinous cystadenomas (32.5%) and most of these were anechoic cysts with septations (55.5 %). Mucinous cystadenocarcinoma was the commonest malignant tumor. Thirty percent of these tumors were cystic with internal echoes, 20% were cysts with septations and 30% were complex predominantly

TABLE I:
HISTOLOGICAL TUMOR TYPE AND ULTRASOUND ECHO PATTERN

Histological Tumor Type	No. of Cases	Ultrasound Echo Pattern					
		Solid	Complex		Cystic		
			>50% Solid	>50% Cystic	Septations	Internal echoes	Clear
Mucinous cystadenoma	27			18.52%	55.55%	11.11%	14.82%
Mucinous cystadenocarcinoma	10		30%	20%	20%	30%	
Serous cystadenoma	9			22.22%	22.22%		55.56 %
Serous cystadenocarcinoma	5		40 %	60%			
Teratoma	7		28.57%	71.43%			
Granulosa cell tumor	5	40%	60%				
Dysgerminoma	1		100%				
Endometrioma	9		11.11%	11.11%		77.78%	
Follicular cyst	6				33.34%	16.66%	50%
Krukenberg tumor	2		100%				
Berkits lymphoma	1		100%				
Cystic lymphosarcoma	1		100%				

solid and 20% were predominantly cystic in appearance. Of these, 10.89% of the tumors were serous cystadenomas. Majority (55.55%) of these were clear cysts, 22.22 % had septations and 22.22% had solid component. Serous cystadenocarcinoma was the second common malignant ovarian tumor (6.02%). In this series, 40% were complex predominantly solid and 60% were cystic with solid component. All teratomas were diagnosed on ultrasound and were benign. These showed typical features of teratomas that is echogenic material, calcification, solid component and fat fluid level. Granulosa cell tumors were solid in appearance. Dysgerminomas and Krukenberg tumors were complex predominantly solid in appearance. Endometriomas were 10.8% of the tumors and most of these were cystic with internal echoes. Most of the follicular cysts (50%) were anechoic in appearance while 33.33% were with septations and 16.66% had internal echoes.

DISCUSSION

In earlier studies by Moyle et al⁷ and Trinidad et al⁸, it has been reported that anechoic masses are benign. Our findings are consistent with this as all clear cysts were benign in this study. Masses showing solid component and thick septations are considered as malignant on ultrasound, but histopathology showed that 27.58% of the tumors with solid component on ultrasound were benign. It was found that this appearance was due to the presence of thick mucinous material adherent to the cyst wall and to the

septa. In haemorrhagic cysts, complex appearance is due to the presence of organized blood. Eighty percent of the malignant tumors have solid component and 20% are cystic with septation. Incidence of serous cystadenocarcinoma is 3-4 times more than that of mucinous cyst adenocarcinoma but in the present study, mucinous cyst adenocarcinoma was more prevalent. Muzaffar et al⁹ also reported similar incidence in Pakistani women. This may be related to genetic, environmental or racial factors. Specific pathological diagnosis of teratomas can be made by ultrasound when highly echogenic focus, calcification and fat fluid levels are seen. This appearance is due to the presence of hair, sebaceous material and teeth in them.

This study shows that anechoic cystic masses have high probability of being benign. Possibility of malignancy increases with the presence of solid component, predominately solid tumors are most likely to be malignant. The stage of ovarian carcinoma at diagnosis directly affects prognosis. Thus, pre operative evaluation is basic to the successful management of ovarian mass. Among currently available imaging techniques for characterization of suspected ovarian neoplasms, sonography is undisputedly the primary imaging approach. When ultrasound is inconclusive, magnetic resonance imaging is helpful. Multimodal approach by the use of transvaginal color Doppler ultrasound, CA 125 estimation and magnetic resonance imaging sensitivity and specificity can further improve the diagnosis of malignant tumor^{10,11}.

REFERENCES

1. Peel KR. Benign and malignant ovarian tumors. In: Dewhursts textbook of obstetrics and gynaecology for post graduates, Blackwell Science, 5th ed. 1995. 759-779.
2. Mann WJ. Diagnosis and management of epithelial cancer of the ovary. Am Family Physician 1994; 49 (3): 613-618.
3. Dembo A.J, Dawy M, Sten Wiog AE et al. Prognostic factors in patients with stage I epithelial ovarian cancer. Obstet Gynaecol 1990; 75: 263-273.
4. Robert WK. Magnetic resonance imaging of tumors. In: the year book of Royal College of Obstetrics and Gynaecology 1994; 195-204.
5. Hirai T, Akamatsu N, Sekiba K et al. Qualificated discrimination of ovarian malignancy by diagnostic ultrasound. Asia Oceania J Obstet Gynaecol 1993; 19(2): 181-189.
6. Servo SF, Scully RE, Sobin LH. International histological classification of tumors (Number IX): histological typing of ovarian tumors. WHO. Geneva, 46-50.
7. Moyle JW, Rochester D, Sider L et al. Sonography of ovarian tumors: predictability of tumor type. Am J Roentgenol 1983; 141: 985-991.
8. Trinidad MA et al. Ultrasonic evaluation and classification of ovarian tumors. Asia Oceania J Obstet Gynecol 1986; 12 (1): 89-97.
9. Muzaffar M, Iftikhar AM, Saeeda AA. Clinico-pathological study of 107 ovarian tumors. J Pak Med Assoc 1987: 194-197.
10. Swicki W, Spiewankiewicz B, Cendrawski K. Transvaginal Doppler Ultrasound with colour flow imaging in benign and malignant lesions. Clin Exp Obstet Gynecol 1995; 22 (2): 137-42.
11. Huber S, Medl M, Baumann L. Value of ultrasound and magnetic resonance imaging in the preoperative evaluation of suspected ovarian masses. Anticancer Res 2002 (4): 2501-7.



AUTHOR AFFILIATION:

Dr. Nishat Zohra

Assistant Professor, Department of Gynaecology and Obstetrics
Isra University, Hala Road, Hyderabad, Sindh, Pakistan