

SHEATHOTOMY FOR TREATMENT OF BRANCH RETINAL VEIN OCCLUSION

Abdul Rasheed Khokhar and Ziauddin Ahmed Shaikh

ABSTRACT

OBJECTIVE: To evaluate visual outcome after arteriovenous sheathotomy for the treatment of branch retinal vein occlusion (BRVO).

DESIGN: A descriptive case review.

SETTING: Civil Hospital and Dow University of Health Sciences, Karachi, Sindh - Pakistan.

METHODS: A pars plana vitrectomy and dissection of the involved AV crossing site were performed consecutively in 20 eyes of 20 patients with BRVO and vision loss. The overlying retinal artery was dissected free from the retinal surface, and separation of the artery and vein at the crossing site was attempted.

RESULTS: In 19 of 20 eyes, the retinal artery was dissected around the crossing site. After a mean follow-up of 10.5 months, VA improved by at least two lines or more in 16 eyes (80%), remained unchanged in two eyes (10%), and worsened by at least two lines in two eyes (10%). Mean change (\pm SE) in logMAR acuity was -0.28 ± 0.11 ; two or three lines of improvement ($P=0.016$) at 1 to 2 months' follow-up and -0.44 ± 0.14 ; three or four lines of improvement ($P = 0.008$) at the final follow-up. Cataract formation or progression occurred in 88% cases.

CONCLUSION: A surgically important adhesion between the retinal artery and vein at proximal AV crossings was encountered in all eyes undergoing AV sheathotomy. Cataract formation was a frequent complication. Visual improvement may occur after vitrectomy and AV sheathotomy without separation of the retinal vessels.

KEY WORDS: Sheathotomy. Branch retinal vein occlusion. Pars plana Vitrectomy. Macular edema.

INTRODUCTION

Branch retinal vein occlusion (BRVO) is a common retinal vascular disorder, second only to diabetic retinopathy as a cause of retinal vascular disturbance.^{1,2} The interruption of venous flow in these eyes almost always occurs at a retinal arteriovenous intersection, where a retinal artery crosses a retinal vein.³ BRVO is three times more common than CRVO. Men and women are affected equally.^{4,5} The artery nearly always is anterior to the vein.⁶ Several medical and surgical interventions have been proposed to treat BRVO. The Branch retinal vein occlusion study demonstrated that Argon laser Photocoagulation may reduce visual loss from persistent macular edema and retinal neovascularization. But, photocoagulation is ineffective for restoring blood flow.⁷ Pars plana vitrectomy with surgical separation of the retinal artery from the underlying retinal vein at the site of pathological arteriovenous crossing has been advocated as a potential treatment for a branch vein occlusion and associated visual loss.^{8,9} Increased risk of branch retinal vein occlusion has been observed in individuals with a history of systemic hypertension and cardiovascular

disease.¹⁰ Shah, et al¹¹ have reported good results of the technique in 4 of 5 patients. Recently, Mester and Dillinger¹² have published good functional results in 43 prospective cases. Poor visual prognostic factors include advancing age, male sex as well as worse baseline visual acuity.¹³

PATIENTS AND METHODS

This study was performed on 20 consecutive patients with a branch vein occlusion and secondary macular dysfunction who underwent arteriovenous crossing dissection with attempt surgical separation of the artery and vein. Inclusion criteria were visual acuity of 20/60 or worse, less than 10 month duration. Exclusion criteria were presence of other vasculopathies, previous Grid laser photocoagulation and vitreous hemorrhage or retinal neovascularization.

The pre-operative data from the patients included age, sex, eyes affected, duration of symptoms, refraction and best corrected visual acuity measurement. All 20 eyes underwent indirect ophthalmoscopy, slit lamp examination including biomicroscopy of the vitreous and retina. Fundus photography and FFA were also

performed in each patient. Duration of study was between June 2002 and June 2004 and it was performed at Advanced Eye Clinic and Civil Hospital, Karachi, Sindh - Pakistan.

The surgical procedure consisted of a pars plana vitrectomy with separation of posterior hyaloid. A Bent tipped MVR blade was used to dissect the overlying retinal artery free from the retinal surface immediately proximal and distal to the pathologic arteriovenous crossing site. The artery was usually approached from both sides using a stroking motion of the blade tip. By connecting the incision from both sides of the artery, the artery was freed from the retinal surface.

Post-operative follow up was performed from 1-2 months, 3-4 months and more than 6 months (final follow up). Subsequent FFA was assessed at varying intervals post-operatively, most of which had been performed from 3 to 5 months after surgery. For statistical analysis, the un-paired t-test was used to determine statistical significance with an alpha of 0.05.

RESULTS

Twenty patients underwent a pars plana vitrectomy and sheathotomy consecutively. Eleven patients were males and nine females. The mean age was 69 years (Range = 39-84 years). The median duration of symptoms of vision loss was 16 weeks (Range= 6-156 weeks). Post-operative follow up was 01 to 15 months. In all cases, the artery was located anterior to the retinal vein at affected anterior venous crossing. In 10 of 20 patients (50%), dilation of the involved retinal vein was observed concomitantly with arteriovenous crossing dissection. This was interpreted as possibly indicating an increase in blood flow at the time of surgery. The mean pre-operative visual acuity was 1.11 (20/260 Snellen's equivalent), while the mean final visual acuity was 0.67 (20/90 Snellen's equivalent). The mean change in visual acuity \pm SEM (Final log MAR minus pre-operative log MAR) was -0.44 ± 0.14 ; equivalent to approximately four lines of Snellen visual acuity improvement ($P=0.008$) (**Figure-1**). Ten of 16 patients who had visual impairment of two or more lines at the final follow up examination experienced such improvement within 1 to 2 months of surgery (**Tables-I-III**). Fundus Fluorescein Angiography was available for review in 13 eyes (65%) at 3-5 months interval. At this interval, there appeared to be reduction of the fluorescein leakage in nine eyes (45%), no change in three eyes (15%), and the worsening in one eye (5%). Intra-operative complications fortunately did not occur. Post-operative complications included cataract in 15 of 17 eyes (88%) and retinal detachment in

one eye (5%).

**TABLE-I:
RATE OF VISUAL ACUITY CHANGE, RELATIVE TO
PREOPERATIVE VISUAL ACUITY, BY DURATION
OF FOLLOW-UP, DURATION OF POSTOPERATIVE
FOLLOW-UP (n=20 patients)**

Snellen's visual Acuity Change	1-2 mo, n (%)	3-4 mo, *n (%)	5-15 mo, n (%)
Improved > 2 lines	10 (50)	10 (50)	16 (80)
Stable	9 (45)	5 (25)	2 (10)
Worsened > lines	1 (5)	2 (10)	2 (10)
Mean change in log MAR	--0.28	--0.38	--0.44
	(P = 0.016)		(P = 0.008)
Approximate Snellen's equivalent (average change)	Imp. 2 Lines	Imp. 3 Lines	Imp. 4 Lines

* 3-4 months follow-up data not available for three patients; Data analyzed by t-test.

**TABLE II:
PRE-OPERATIVE PATIENT CHARACTERISTICS**

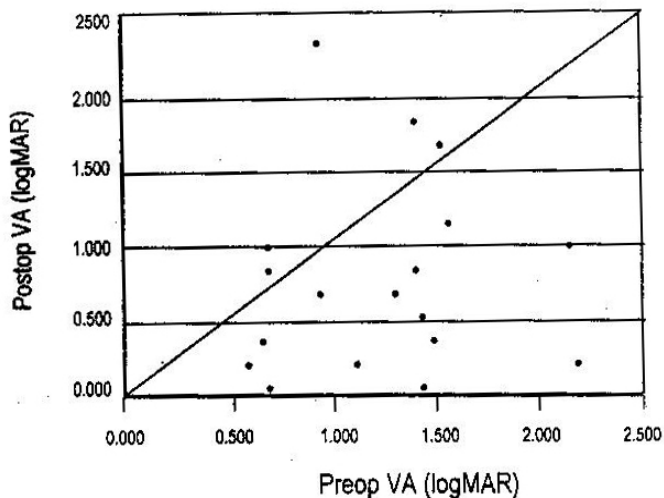
Characteristic	Number of Eyes (%)
Macular edema and retinal hemorrhage precluding laser therapy	14 (70)
Macular edema unresponsive to laser	3 (15)
Macular edema alone	2 (10)
Macular ischemia alone	1 (5)

**TABLE III:
PRE-OPERATIVE AND FINAL VISUAL ACUITY**

Visual Acuity	Pre-operative Visual Acuity	Final Visual Acuity
20/20-20/50	1 (5%)	10 (50%)
20/60-20/160	8 (40%)	5 (25%)
20/200 or worse	11 (55%)	5 (25%)

FIGURE I:

GRAPH OF FINAL POST-OPERATIVE VISUAL ACUITY PLOTTED AGAINST PREOPERATIVE VISUAL ACUITY (LOGMAR IN 20 PATIENTS WHO UNDERWENT ARTERIOVENOUS CROSSING DISSECTION. POINTS BELOW THE DIAGONAL LINE INDICATE VISUAL GAIN; POINTS ABOVE INDICATE VISUAL LOSS.



DISCUSSION

In our series, pars plana vitrectomy and dissection of the arteriovenous crossing without separation of the vessels was associated with visual acuity improvement of two or more lines in 80% of patients with BRVO and macular dysfunction. Visual acuity of 20/50 or better was obtained in 50% of patients, with an average visual acuity improvement of four lines. Our visual results are similar to those of Opremcak and Bruce¹⁴, who accomplished arteriovenous separation in 50 patients. They reported visual improvement of one or more lines in 76% of patients and final visual acuity of better than 20/60 in 42% after a mean follow-up of 8 months, similar to their previously published report of 15 cases, which also reported encouraging results.¹¹ None of the above studies incorporated a randomized control group managed with observation or laser photocoagulation. Because of the possibility of spontaneous improvement in branch retinal vein occlusion, it cannot be determined with certainty whether improvement after surgery in any of the above series was due to the natural course of the condition or a direct result of the procedure. A recent case-control study of branch retinal vein visual outcome by vitrectomy and arteriovenous sheathotomy compared to grid laser photocoagulation.¹⁵

The mechanism by which improvement may occur after dissection of the artery from the retinal surface around an arteriovenous crossing site without surgical separation of the vessels remain speculative. Seitz¹⁶

hypothesized that the initiating abnormality in venous occlusion is "not a thrombus, but a trophic disturbance" related to the anatomic structure of the arteriovenous crossing that occurs within a framework of systemic arteriosclerosis or hypertension. He observed acute endothelial changes and narrowing of the vascular lumen and hypothesized that the resulting turbulent flow caused edema, necrosis, and in some instances, rupture of the vessel wall. Some of his histological specimens also show apparent displacement of the course of the occluded vein, as it curves beneath an overlying artery that is positioned within the substance of the retina. Such a configuration may conceivably result in turbulent venous flow. Alteration of this configuration of the vessels by surgical displacement of the artery into a position anterior to the retina in some way, reverse a pathologic state responsible for venous insufficiency.

Surgical adhesion between the artery and vein at proximal arteriovenous crossings correlates with histopathologic findings of a common vascular wall observed in cases of branch retinal vein occlusion¹⁶ and with studies of human cadaver eyes that underwent surgical manipulation of the retinal vasculature.¹⁷ Conceivably, unless the conjoined vascular tissues are precisely divided, separation of the two vessels may result in a defect or tear in a vessel wall. No reports of complications relating to this aspect of surgical separation have yet been reported, despite many surgeries having been performed.

REFERENCES

1. Orth DH, Patz A. Retinal branch vein occlusion. *Surv Ophthalmol.* 1978; 22: 357 – 376.
2. Branch Vein Occlusion Study Group. Argon Laser Scatter Photocoagulation for prevention of Neovascularization and vitreous hemorrhage in branch vein occlusion. *Arch Ophthalmol.* 1986; 104:34 – 41.
3. Frangiegh GT, Grean WR, Barraquer – Sommers E, et al. Histopathologic study of nine retinal vein occlusions. *Arch Ophthalmol.* 1982;100:1132 - 1140.
4. Mitchell P, Smith W, Change A. Prevalence and association of retinal vein occlusion in Australia. *Arch Ophthalmol.* 1996;114:1243-7.
5. Hayreh SS, Zimmerman MMB, Podhajsky P. Incidence of various types of retinal vein occlusion. *Am J Ophthalmol.* 1994;17:429-41.
6. Duker JS, Brown GL. Anterior location of the crossing artery in branch retinal vein occlusion. *Arch Ophthalmol.* 1989;107:998 – 1000.
7. Branch Vein Occlusion Study Group. Argon Laser Photocoagulation for macular edema in branch

- vein occlusion. Am J Ophthalmol. 1993;116:286-296.
8. Asterloh MD, Charles S. Surgical decompression of BRVO. Arch Ophthalmol. 1988;106:1469-1471.
 9. Opremcak EM, Bruce RA. Surgical decompression of branch retinal vein occlusion via arteriovenous crossing sheathotomy; a prospective review of 15 cases. Retina. 1999;19:1-5.
 10. The Eye Disease Case Control Study Group. Risk factors for BRVO. Am J Ophthalmol. 1993;116:286 – 296.
 11. Shah GK, Sharma S, Fineman MS, et al. Arteriovenous adventitial sheathotomy for the treatment of macular edema associated with BRVO. Am J Ophthalmol. 2000;129:104-106.
 12. Mester U, Dillinger P. Vitrectomy with arteriovenous decompression and ILM dissection in BRVO. Retina. 22:740 – 746.
 13. Glact – Bernard A, Corces G, Chabanel A, Zourdan A, Lelong F, Samama MM. Prognostic factors for retinal vein occlusion. A prospective study of 175 cases. Ophthalmology. 1996;103:551 – 60.
 14. Opremea KEM, Bruce RA. Arteriovenous sheathotomy for branch retinal vein occlusion. Retina. 2001.
 15. Tachi N, Hashimoto Y, Ogino N. Vitrectomy for macular edema combined with retinal vein occlusion. Doc Ophthalmol. 1999;97:465 – 469.
 16. Seitz R. The retinal vessels comparative ophthalmoscopic and histologic studies on healthy and diseased eye. St. Louis: CV Mosby 1946;186.
 17. Tang WM, Han DP. A study of surgical approaches to retinal vascular occlusion. Arch Ophthalmol. 2000;118:138 – 143.

**AUTHOR AFFILIATION:**

Dr. Abdul Rasheed Khokhar (*Corresponding Author*)
Assistant Professor
Department of Ophthalmology
Civil Hospital and Dow University of Health Sciences,
Karachi, Sindh - Pakistan.

Prof. Ziauddin Ahmed Shaikh
Chairman
Department of Ophthalmology
Civil Hospital and Dow University of Health Sciences,
Karachi, Sindh - Pakistan.