

# Combined Pars Plana Lensectomy-Vitreotomy for Management of Hereditary Ectopia Lentis

Abdul Fatah Memon, Waseem H. Jafri, Fahad F. Shaikh

## ABSTRACT

**OBJECTIVE:** To assess the visual outcome and complications of Combined Pars Plana Lensectomy-Vitreotomy in hereditary ectopia lentis.

**STUDY DESIGN:** Prospective observational study.

**SETTINGS:** Al-Ibrahim Eye Hospital, Isra Postgraduate Institute of Ophthalmology, Karachi; from Jan' 2004 to Dec' 2007

**SUBJECTS AND METHODS:** Forty eyes of 23 patients diagnosed as having hereditary ectopia lentis were included in the study. All the cases were worked up according to the standard protocol and were operated upon. The surgical procedure adopted was pars plana lensectomy with core vitrectomy. Endolaser photocoagulation was performed in selected cases.

**RESULTS:** Forty (40) eyes of 23 patients with ectopia lentis of hereditary type were included in the study. Seventeen patients had bilateral and 6 patients had unilateral ectopia lentis. There were 8 male and 15 female patients. Age range was 5 – 29 years. Preoperative visual acuity was 6/12 – 6/18 in 4 (10%) eyes; 6/24 – 6/60 in 28 (70%) eyes and < 6/60 in 8 (20%) eyes. Postoperative corrected visual acuity was 6/6 - 6/9 in 28 (70%) eyes; 6/12 – 6/18 in 4 (10%) eyes; 6/24 – 6/60 in 6 (15%) eyes and less than 6/60 in 2 (5%) eyes. Intra-operative complications were accidental iris injury in 1 eye and dropped lens fragment into the vitreous cavity in 1 eye. Post-operative complications were transient ocular hypertension in 2 eyes and persistent postoperative uveitis and vitritis in 1 eye.

**CONCLUSION:** Pars plana approach for management of ectopia lentis is a safe and effective method of treatment.

**KEY WORDS:** Hereditary, Ectopia lentis, Pars plana lensectomy-vitreotomy, Endolaser photocoagulation, Visual acuity.

## INTRODUCTION

Ectopia lentis is defined as subluxation or dislocation of the crystalline lens. It is a quite commonly encountered problem, and often creates difficult management problems. Etiologically, it may be divided into hereditary and acquired types. The hereditary causes include familial ectopia lentis, ectopia lentis associated with ocular anomalies, and ectopia lentis associated with systemic disorders such as Marfan's syndrome, homocystinuria and Weil-Marchesani syndrome<sup>1</sup>. Mechanisms for vision loss include lenticular myopia and astigmatism, anisometropia, pupillary block glaucoma, and corneal endothelial damage. Management initially involves refractive correction but may require lens removal when visual acuity becomes uncorrectable or the refractive status is unstable<sup>2</sup>.

Indications for surgery are best-corrected visual acuity (BCVA) less than 6/18, bisection of the pupil by the lens with resultant diplopia, optical aberrations, cataract, lens-induced glaucoma and forward subluxation of lens into the anterior chamber<sup>3</sup>. Lens extraction has traditionally been performed through a limbal incision but this may be associated with a high rate of compli-

cations, including vitreous loss, retinal detachment, dropped lens and glaucoma<sup>4</sup>. Combined pars plana lensectomy-vitreotomy (PPL/PPV) has been described for removing subluxated crystalline lenses and it has greatly improved the surgical results and minimized operative complications<sup>5</sup>. Advantages of the pars plana surgical approach include a closed ocular surgical system, minimal corneal trauma, limited iris trauma, and good vitreous control; and the surgical approach offers an easy route to repair retinal problems if they are present or develop during the course of surgery.<sup>2,6</sup>

This study is important in evaluating the results of this relatively new surgical technique in our setup, since no study has been published in local literature on combined pars plana lensectomy-vitreotomy before; this will enable the researcher to compare the results with those of other centers around the world.

## SUBJECTS AND METHODS

This study was conducted at Al-Ibrahim Eye Hospital, Isra Postgraduate Institute of Ophthalmology, Karachi during Jan' 2004 to Dec' 2007. During this period 40 eyes of 23 patients with ectopia lentis of hereditary

type were selected from the out-patient department of the hospital. Complete ocular examination was performed to detect any associated pathology, with special emphasis on refractive error, intraocular pressure (IOP) and peripheral retinal degeneration. Gonioscopy was performed in patients with raised IOP to look for anterior chamber angle anomalies. Patients were examined systemically to look for systemic association. Urine homocysteine level was checked to confirm the diagnosis of Homocystinuria. Echocardiography was advised in patients with Marfan's syndrome.

The indications for surgery in our patients were decreased best-corrected visual acuity (BCVA) less than 6/18 (33 eyes), lens-induced glaucoma (2 eyes), forward subluxation of lens into the anterior chamber (3 eyes) and cataract (2 eyes). Informed consent was obtained for the surgery. Patients with pupil block were admitted and advised to lie in supine position; pupil was dilated with Tropicamide 1% eye drops and intravenous Mannitol 1mg/kg was given so as to facilitate posterior migration of lens into the posterior chamber. IOP was controlled medically before surgery. The surgical procedure consisted of standard (20 gauge) three-port pars plana approach under local or general anaesthesia. A 4-mm infusion cannula was placed through the infero-temporal sclerotomy. A surgical micro vitreo-retinal (MVR) blade was introduced into one of the superior sclerotomies and passed through the equator and nucleus of the lens. The surgical blade was then removed and vitrectomy cutter and fiberoptic endoilluminator was inserted through the superior sclerotomies. The nucleus and the cortex were aspirated with minimal cutting with the vitreous cutter. The fiberoptic endoilluminator was used to support the subluxated lens to prevent lens drop. The anterior and central vitreous down to optic nerve (core vitrectomy) was removed with vitreous cutter. For cataractous lens, ultrasonic phaco-fragmentor was used to emulsify the nucleus. The peripheral retina was meticulously examined by using binocular indirect ophthalmomicroscope (BIOM) and scleral indentation. Fourteen eyes had peripheral retinal lattice degeneration and were prophylactically treated with endolaser photocoagulation. The sclerotomies were closed using absorbable suture.

Postoperatively, immediate visual rehabilitation was achieved by aphakic correction with spectacles. This was followed later by scleral fixation of intraocular lens<sup>6</sup>. Four patients in 5-8 years age group, that were susceptible to amblyopia, were operated on both eyes in the same sitting; they were then prescribed refractive correction after 1 week of surgery.

All the relevant information was recorded in a specially

designed questionnaire. Male to female ratio for presentation of sex distribution was computed. Mean age was calculated and age groups were classified. Variables including etiology of ectopia lentis, preoperative best-corrected visual acuity, post-operative visual status, operative and postoperative complications were presented by frequencies and percentages.

## RESULTS

Forty eyes of 23 patients with ectopia lentis of hereditary type were included in the study. Seventeen (74%) patients had bilateral and 6 (16%) patients had unilateral ectopia lentis. There were 8 (34%) male and 15 (66%) female patients. Age range was 5-29 (mean=18) years. There were 4 patients in 5-8 year age group; 6 patients in 9-15 year age group and 13 patients were older than 15 years. Patient diagnoses are given in **Table I**.

Intraocular pressure was raised more than 22-mmHg in 4 (10%) eyes because of lens induced pupillary block in 2 eyes and angle anomaly in 2 eyes. Fundoscopy revealed lattice degeneration was seen in 14 (35%) eyes. The indications for surgery in our patients were decreased BCVA less than 6/18 (33 eyes), lens-induced glaucoma (2 eyes, having BCVA 6/18 or better), forward subluxation of lens into the anterior chamber (3 eyes; 2 of them having BCVA 6/18 or better) and cataract (2 eyes).

Preoperative and postoperative visual status is given in **Table II**.

Intra-operative complications were, accidental iris injury in 1 eye and dropped lens fragment into the vitreous cavity in 1 eye. Post-operative complications were transient ocular hypertension in 2 eyes and persistent postoperative uveitis in 1 eye (**Table III**). Retinal detachment was not seen in any of the 4 eyes that underwent endolaser photocoagulation till the last follow-up.

**TABLE I: ETIOLOGY OF ECTOPIA LENTIS (n=23)**

Etiology	No. of Patients (%)
Marfan's Syndrome	11 (48)
Simple Ectopia Lentis	05 (22)
Weill Marchesani Syndrome	03 (13)
Homocystinuria	02 (08)
Stickler's syndrome	01 (04)
Ectopia lentis et pupillae	01 (04)

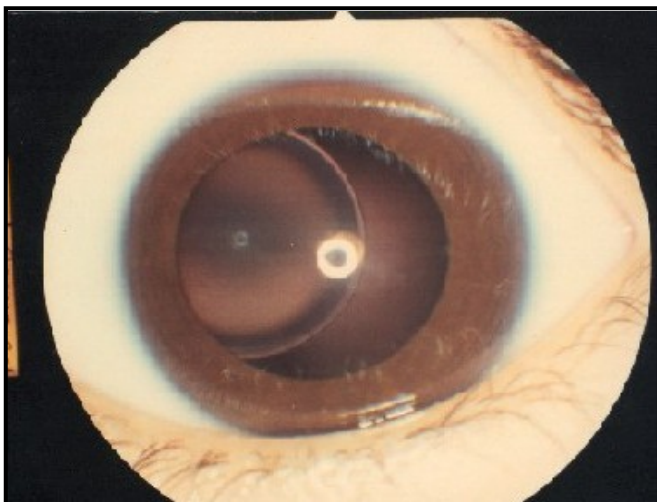
**TABLE II: VISUAL STATUS (n=40)**

	Pre-operative	Post-operative
Visual Acuity	No. of Eyes (%)	No. of Eyes (%)
6/6 - 6/9	00	28 (70)
6/12 – 6/18	04 (10)	04 (10)
6/24 – 6/60	28 (70)	06 (15)
< 6/60	08 (20)	02 (5)

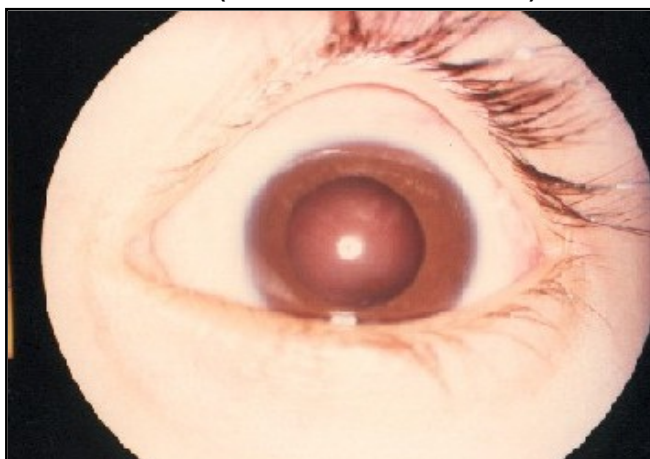**TABLE III: COMPLICATIONS**

	Complications	No. of Eyes (%)
Per-operative	Iris Injury	01 (2.5)
	Dropped Lens Fragment	01 (2.5)
Postoperative	Transient Raised IOP	02 (5)
	Persistent Uveitis	01 (2.5)

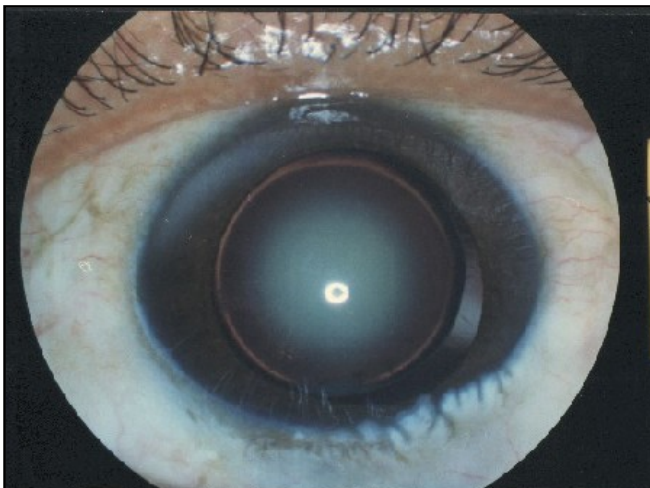
**FIGURE I: SUPEROTEMORAL LENS SUBLUXATION IN MARFAN'S SYNDROME**



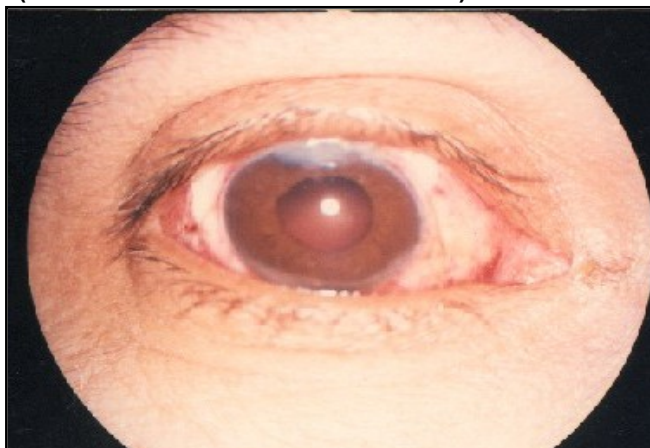
**FIGURE II: POST OPERATIVE PHOTOGRAPH OF SAME EYE AS IN FIGURE I (MARFAN'S SYNDROME)**



**FIGURE III: MICROSPHEROPHAKIA AND LENS SUBLUXATION IN WEILL - MARCHESANI SYNDROME**



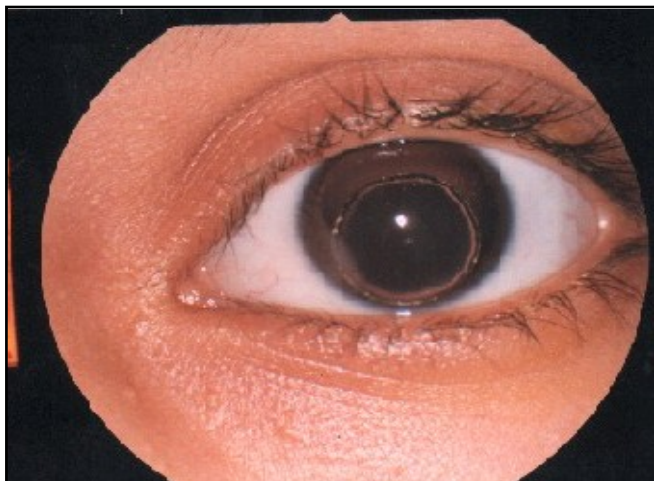
**FIGURE IV: POST OPERATIVE PHOTOGRAPH OF SAME EYE AS IN FIGURE 03 (WEILL MARCHESANI SYNDROME)**



**DISCUSSION**

Management of ectopia lentis is challenging and certain controversies remain unresolved<sup>2</sup>. The initial step is to diagnose the underlying disorder. Reduced vision is managed by careful refraction, both through the lens and through the aphakic space. In many cases, this step avoids or postpones surgery indefinitely<sup>2</sup>. The limbal approach for lens removal has been associated with numerous complications, including vitreous loss, retinal detachment, dropped lens and glaucoma<sup>7</sup>. Newer methods employing a pars plana approach are theoretically more invasive; nonetheless, data for this approach are encouraging. Various reports<sup>8-12</sup>

**FIGURE V: ANTERIOR SUBLUXATION OF LENS IN PATIENT WITH HOMOCYSTINURIA**



describe high rates of visual improvement and low rates of complications after combined pars plana lensectomy-vitrectomy. After the lens has been removed, the next decision is how to rehabilitate the aphakic eye. One option is to leave it aphakic and prescribe spectacles or a contact lens; other alternates are placement of an intraocular lens (IOL) into the anterior chamber (AC-IOL)<sup>2</sup> or scleral fixation of IOL<sup>13</sup>.

In this study, the visual outcome was quite good; 32 (80%) eyes achieved postoperative BCVA 6/18 or better. In 8 (20%) eyes, postoperative BCVA less than 6/18 was attributable to glaucomatous optic nerve damage in 2 eyes of 1 patient and to amblyopia in 6 eyes. Also the number of intra-operative and postoperative complications was low. Intra-operative complications were accidental iris injury in 1 (2.5%) eye and dropped lens fragment into the vitreous cavity in 1 (2.5%) eye. Early post-operative complications were transient ocular hypertension in 2 (5%) eyes; 1 (2.5%) eye that had peroperative dropped lens fragment into the vitreous cavity showed prolonged postoperative anterior uveitis and vitritis for about 4 weeks and eventually resolved with systemic and periocular steroids. These 4 eyes, which experienced some sort of complications, achieved BCVA 6/18 or better in the postoperative period. No late postoperative complication was seen in our patients over a follow up period of 6 months to 3 years. Other possible complications with PPL/PPV reported in the literature<sup>14</sup> are glaucoma, wound dehiscence with iris incarceration, vitreous hemorrhage, peripheral anterior synechiae and retinal detachment.

Similar excellent visual results with low rate of complications have been reported in the literature. Peyman and associates<sup>11</sup> reported a series of 32 eyes with ectopia lentis treated surgically with pars plana approach. Excellent results with no major intraoperative

or postoperative complication were documented. Paul D Reese<sup>10</sup> reported visual acuity better than 20/40 in 11 of 12 eyes underwent pars plana lensectomy without any intra-operative or post-operative complication. Shortt AJ et al<sup>15</sup> reported the results of pars plana lensectomy for non-traumatic ectopia lentis in 24 eyes of 13 patients; postoperative vision was 6/12 or better in 19 eyes. Other than contact lens-related problems, they did not observe any perioperative or postoperative complications. Wu-Chen and associates<sup>14</sup> reported a series of 11 consecutive patients with bilateral ectopia lentis who underwent lensectomy-anterior vitrectomy; postoperative BCVA in 14 eyes was 20/30 and the complications they experienced were glaucoma, wound dehiscence with iris incarceration, transient vitreous hemorrhage and peripheral anterior synechiae. Halpert M et al<sup>16</sup> have published good visual results following PPL in 37 children (59 eyes) with hereditary ectopia lentis. Retinal detachment was detected in one eye 2 years after surgery and was the only major postoperative complications observed in their study<sup>16</sup>.

Pars plana lensectomy-vitrectomy allows excision of vitreous prior to lenticular manipulations, enables lens removal in a closed ocular system, maintains normal anatomic relationship within the globe, and limits vitreous prolapse. It provides excellent intraoperative access to the posterior pole, enables clear visualization of peripheral retina with BIOM and scleral indentation, and allows for simultaneous treatment of peripheral retinal disease<sup>2</sup>. Another relatively recent surgical technique for ectopia lentis is sutured capsular tension ring (CTR)<sup>17</sup> that is also claimed to be safe and effective for ectopia lentis in children but it does not allow simultaneous treatment of peripheral retinal disease.

## CONCLUSION

Combined pars plana lensectomy-vitrectomy is a safe and effective technique for the management of ectopia lentis, with good visual outcome and few complications. However amblyopia remains a major cause of decreased vision even after successful surgery.

## REFERENCES

1. Streeten BW. Pathology of the lens. In: Albert DM, Jacobiec FA, eds. Principles and practice of ophthalmology. Philadelphia: WB Saunders; 1994:2180-238.
2. Kazemi S, Mieler WF, Koenig SB. Combined pars plana vitrectomy-lensectomy and open-loop anterior chamber lens implantation for subluxated lenses. *Tr Am Ophth Soc* 2000;98:247-53.
3. Halpert M, BenEzra D. Surgery of the hereditary subluxated lens in children. *Ophthalmology* 1996;103:681-6.

4. Guo XM, Chen YZ, Zeng LH. Pars plana lensectomy and anterior vitrectomy for the treatment of congenital subluxated lenses. *Chung Hua Ko Tsa Chih* 1994;30:271-3.
5. Malinowski SM, Mieler WF, Koenig SB. Combined pars plana vitrectomy-lensectomy and open-loop anterior chamber lens implantation. *Ophthalmology* 1995;102:211-6.
6. Jacobi PC, Dietlein TS, Jacobi FK. Scleral fixation of secondary foldable multifocal intraocular lens implants in children and young adults. *Ophthalmology* 2002;109(12):2315-24.
7. Jarrett WH. Dislocation of the lens. *Arch Ophthalmol* 1967;78:289-96.
8. Girard LI. Pars plana lensectomy for subluxated and dislocated lenses. *Ophthalmic Surg* 1981;12:491-5.
9. Plager DA, Parks MM, Helveston EM. Surgical treatment of subluxated lenses in children. *Ophthalmology* 1992;99:1018-23.
10. Reese PD, Weingeist TA. Pars plana management of ectopia lentis in children. *Arch Ophthalmol* 1987;105:1202-4.
11. Peyman GA, Raichand M, Goldberg MF. Management of subluxated and dislocated lenses with vitrophage. *Br J Ophthalmol* 1979;63:771-8.
12. Hubbard AD, Charteris DG, Cooling RJ. Vitreolensectomy in Marfan's syndrome. *Eye* 1998;12:412-6.
13. Sandip M, Anuradha G. Scleral suspension pars-plana lensectomy for ectopia lentis followed by suture fixation of intraocular lens. *Indian J Ophthalmol* 2001;49(2):109-13.
14. Wu-Chen WY, Letson RD, Summers CG. Functional and structural outcome following lensectomy for ectopia lentis. *JAAPOS* 2005;9(4):353-7.
15. Shortt AJ, Lanigan B, O'Keefe M. Pars plana lensectomy for management of ectopia lentis in children. *J Pediatr Ophthalmol Strabismus*. 2004;41(5):289-94.
16. Konradsen T, Kugelberg M, Zetterström C. Visual outcome and complications in surgery for ectopia lentis in children. *J Cataract Refract Surg* 2007;33(5):819-24.



*AUTHOR AFFILIATION:*

**Dr. Abdul Fatah Memon** (*Corresponding Author*)

Assistant Professor, Department of Ophthalmology  
Al-Ibrahim Eye Hospital  
Isra Post Graduate Institute of Ophthalmology  
Old Thana Village, Malir, Karachi, Sindh-Pakistan.  
E-Mail: aiehp@yahoo.com

**Dr. Waseem H. Jafri**

Associate Professor, Department of Ophthalmology  
Al-Ibrahim Eye Hospital  
Isra Post Graduate Institute of Ophthalmology  
Karachi, Sindh-Pakistan.

**Dr. Fahad F. Shaikh**

Assistant Professor, Department of Ophthalmology  
Isra University and Hospital  
Hyderabad, Sindh-Pakistan.