

Retained Surgical Sponge Following Abdominal Surgery

Syed Asim Ali Jaffary, Shabnam Shamim Asim, Saleha Anwar, M. Shahid Shamim

ABSTRACT

OBJECTIVE: To share the experience of gossypiboma cases, their presenting features, pre-operative risk factors and post-operative outcome in terms of complications and recovery.

STUDY DESIGN: Retrospective study.

PLACE AND DURATION OF STUDY: Several government and private hospitals of Karachi, over an operative experience exceeding 35 years for the principal author and 15 years for the co-authors.

PATIENT AND METHOD: This study includes collective personal operative experience with patients having gossypibomas. It is compiled by two general surgeons and one gynecologist. Data of 14 cases with primary diagnosis of gossypiboma were reviewed and analyzed. Literature was searched for relevant information.

RESULT: There were 11 female and 3 male patients. Mean age of the patients was 42 years (range 25 to 59 years). Cesarean section was the commonest surgery performed in 5 patients followed by hysterectomies in 3 patients. Plain radiograph and CT scan abdomen were found to be helpful in diagnosis. Mean interval between initial and final surgeries was eight months (range one week to two years). All patients recovered completely after surgical removal of gossypiboma.

CONCLUSION: Retained sponge was more common in obstetrical procedures performed in emergency. Presence of abdominal mass or intestinal obstruction was the commonest presentation (93%). Micro-air-bubbles in plain abdominal x-ray in a post laparotomy patient appeared to be a diagnostic feature of gossypiboma. CT scan was better than other radiological investigations in identifying the retained sponge.

KEY WORDS: Gossypiboma, retained surgical sponge, retained foreign body, intestinal obstruction, cesarean section.

INTRODUCTION

The term "gossypiboma" denotes a mass of cotton foreign body that is left inadvertently in the human body following a surgical procedure¹. It can be anything from a small gauze piece to abdominal towel. Gossypiboma is rarely reported due to medico-legal consequences.² True worldwide incidence is unknown, however, it has been reported as 1 in 1000 to 1500 in intra-abdominal open surgeries and 1 in 3000 in all surgical interventions³⁻⁴. Although abdominal surgeries are more likely for such complications, it has also been observed in thoracic, orthopedic, cardiovascular and neurosurgical operations²⁻⁶. It was presumed that with the introduction of minimally invasive surgical procedures, surgical sponges with radio-opaque material and better peri-operative protocols such as repeated sponge counting and x-rays in case of missing sponges, the incidence of this morbidity would be almost zero. However, in countries with financial restraints, these protocols are seldom followed and it is therefore imperative that this complication should always be kept in mind. We report our own experience with gossypibomas with intention of better defining the features associated with this com-

plication, as well as the radiological findings helpful for early diagnosis. The objective of this study is to report our personal experience of cases found to have gossypiboma, their presenting features, pre-operative risk factors and post-operative outcome in terms of complications and recovery.

METHODS

This retrospective study includes the cases of gossypiboma operated by the authors in public and private sector hospitals of Karachi over a period spanning 35 years of surgical practice of the principal author, and a mean period of 15 years of surgical practice of co-authors. Case records of patients diagnosed with gossypiboma were retrieved and the required data were transferred onto a predesigned proforma. Variables that were recorded included patients' demography, clinical presentation of the problem, potential risk factors such as obesity, type (elective or emergency) and indication of initial surgery, radiological investigations performed for preoperative diagnosis, surgical procedure performed, type of foreign body retrieved, interval between first and second surgeries, whether diagnosis of gossypiboma was considered preoperatively and outcome of treatment.

Names of surgeons and places of previous surgical procedures were deliberately omitted from data collection for ethical reasons.

Radiological material, where available, was reviewed by one of the authors and reports of all radiological investigations were recorded.

Data were then compiled in MS Excel and analyzed for frequencies and percentages. A detailed literature search was conducted on the topic for comparing our experience with published literature.

RESULTS

We came across a total of fourteen cases of gossypiboma over the study period. There were 3 males and 11 females (ratio 1:3.6). The mean age of the patients was 42 years (range 25 to 59 years).

Seven of the 14 (50%) initial surgeries, during which the sponge was left behind, were elective surgeries, and an equal number were emergency surgeries. Of the elective cases, 3 (42.86%) surgeries were related to general surgery, and 1 (14.29%) to urology. Of the emergency cases, 6 (85.71%) operations were for obstetric and/or gynecological reasons. Overall in 10 (71.43%) cases sponge was left behind during obstetric and/or gynecological cases, 3 (21.43%) during general surgery and 1 (7.14%) urology. Obesity was not a consistent finding in our series and was present in only 4 (28.57%) patients.

Seven (50%) patients presented with an abdominal mass, while intestinal obstruction was present in 6 (42.86%). Only 1 (7.14%) patient presented with a persistent discharging sinus from the surgical incision site (**Table I**). Preoperative diagnosis of retained sponge was made in 5 (35.71%) cases whereas in 9 (64.29%) patients diagnosis was not clear until surgical exploration. CT scan was done in 3 (21.43%) cases, all of them showed cystic mass containing hypodense whirl-like gas collection in the hyperdense solid component of cotton mesh. Intravenous contrast injection resulted in marked enhancement of the thin wall surrounding the lesion (**Figure I**). Ultrasound alone was performed in 3 (21.43%) patients and in 1 patient it was followed by CT scan. Ultrasound suspected the cotton foreign body in 1 case only. Contrast studies were done as part of workup for intestinal obstruction but they did not give the diagnosis of retained abdominal sponge. Plain x-ray of abdomen was done in all patients (**Figure II**).

All patients required laprotomy for the retrieval of abdominal sponge. The interval between initial surgery when abdominal sponge was retained and the final surgery during which sponge retrieved was variable, the mean interval being eight months while minimum and maximum period were one week and two years respectively. Nine (64.29%) patients had formal ex-

ploratory laparotomy. In 1 patient who had cholecystectomy and presented with discharging sinus, the sinus tract was extended under general anesthesia and sponge was removed three weeks after initial surgery. In another patient, skin and muscles sutures were opened and sponge was taken out one week after emergency surgery for ruptured ectopic pregnancy. Retained abdominal sponge was the foreign body found in all of the 14 cases. The postoperative recovery was uneventful in all patients and they were discharged after routine postoperative care and no delayed post-operative sequel (**Table II**).

TABLE I: PRESENTATION OF THE GOSSYPIBOMA

Presentation	Number (%)
Abdominal mass	7 (50)
Subacute intestinal obstruction	4 (28.6)
Acute intestinal obstruction	2 (14.3)
Discharging sinus	1 (7.1)
Total	14 (100)

DISCUSSION

The term gossypiboma is derived from the Latin word gossypium, meaning cotton, and the Kiswahili word boma, meaning place of concealment. There are many case reports of retained foreign bodies in the literature, but the true incidence is thought to be under reported secondary to the possible legal consequence of this technical complication⁷.

According to a recent review, there have been so far 254 gossypiboma cases (147 reports from the period 1963-2008) reported in the medical literature⁷. In this study retained sponge was more common in females (70%). Apart from female gender, other associated factors for gossypiboma were obstetrical and emergency surgeries. These three factors are interrelated as obstetrical procedures are performed only in females and due to the nature of this specialty a significant number of these surgeries are performed in emergency. This is especially more common in Pakistan where very few of these women undergo routine antenatal checks-ups or planned obstetrical procedures, mainly presenting in acute emergency. These results are in accordance with a study of 11 patients, also showing preponderance for females and emergency obstetrical operations with mean age 45 years². One study has found obesity as a risk factor¹ but this was not significant in our study.

Patient with gossypiboma presents either acutely or in a chronic fashion⁷. Those patients who present acutely have infection, sepsis and abscess formation. This is an exudative response that may lead to the

FIGURE I: CT SCAN ABDOMEN WITH A GOSSYPIBOMA ON THE LEFT SIDE

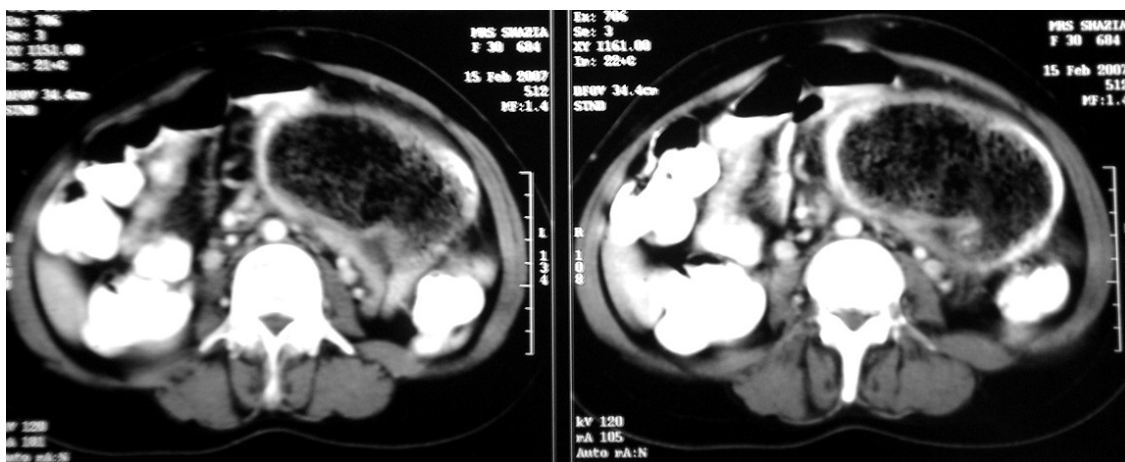


TABLE II: INITIAL SURGERY PERFORMED, INDICATION FOR SECOND SURGERY, DURATION BETWEEN INITIAL AND SECOND SURGERIES, NATURE OF SURGERY PERFORMED AND OUTCOME

Initial surgery	Indication for second surgery	Gap b/w two Surgeries	Second surgery	Outcome
Caesarean Section	Lump in LIF	5 months	Formal laparotomy	Survived
Caesarean Section	Subacute intestinal obstruction	6 months	Formal laparotomy	Survived
Caesarean Section	Mass in lower abdomen	5 months	Formal laparotomy	Survived
Caesarean Section	Mass in LIF	4 months	Formal laparotomy	Survived
Caesarean Section	Mass in lower abdomen	8 months	Formal laparotomy	Survived
Hysterectomy	Lump in Rt. Lower Abdomen	11 months	Formal laparotomy	Survived
Hysterectomy	Acute intestinal obstruction	9 months	Formal laparotomy	Survived
Hysterectomy	Acute intestinal obstruction	8 months	Formal laparotomy	Survived
Ovarian cystectomy	Mass in lower abdomen	7 months	Formal laparotomy	Survived
Laparotomy for ectopic pregnancy	Mass in lower abdomen	1 week	Opening of skin and muscles sutures	Survived
Right hemicolectomy	Subacute intestinal obstruction	2 years	Formal laparotomy	Survived
Open right nephrectomy	Mass in RIF	10 months	Formal laparotomy	Survived
Open cholecystectomy	Discharging sinus	3 weeks	Extension of sinus tract under GA	Survived
Laparotomy for enteric perforation	Subacute intestinal obstruction	1 year 2 months	Formal laparotomy	Survived

complications of perforation, fistulae, intramural or even transmural migration with subsequent obstruction, extrusion per anus or retrieval through endoscopy.^{8,9} In one of the cases, large bile stained abdominal sponge was removed (**Figure III**). After removal of the sponge the cavity revealed presence of two loops of perforated jejunum and a large perforation in the sigmoid colon (**Figure IV**). Such a perfora-

tion in the sigmoid colon has been reported to lead to expulsion of the sponge through anus,^{1,7,8,9} although we did not come across such a presentation in our series.

Patients who present in a delayed fashion have a fibrous abdominal response. This is usually an aseptic process that leads to adhesions and a thick capsule around the retained sponge^{7, 9, 10}. In our study 50% of

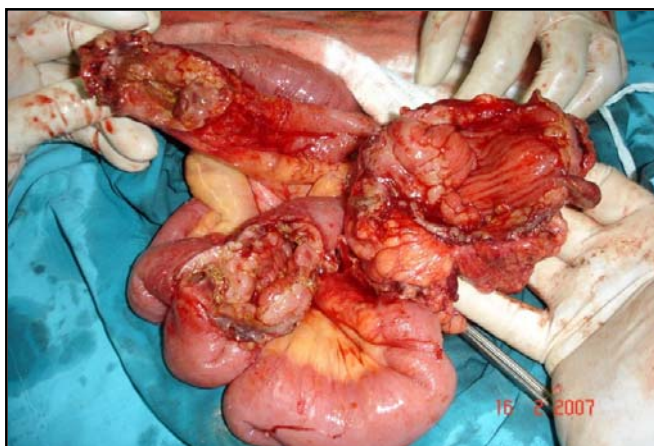
FIGURE II: PLAIN X-RAY ABDOMEN SHOWING MICRO-AIR-BUBBLES ON THE LEFT SIDE

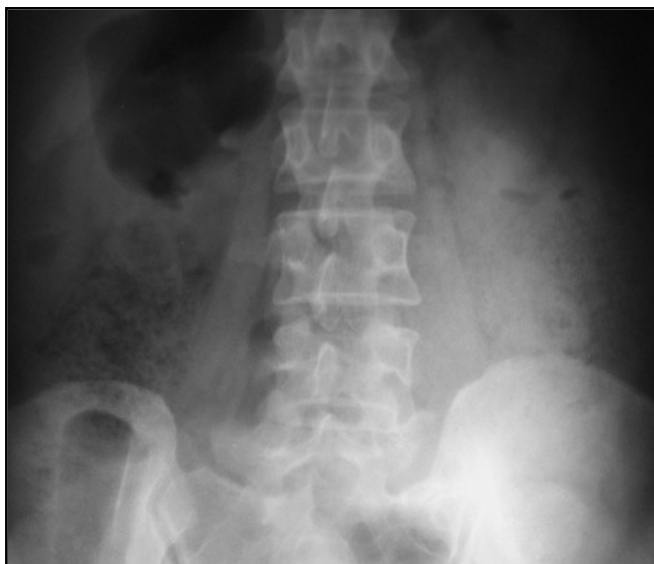

FIGURE III: PER-OPERATIVE RETRIEVAL OF SPONGE

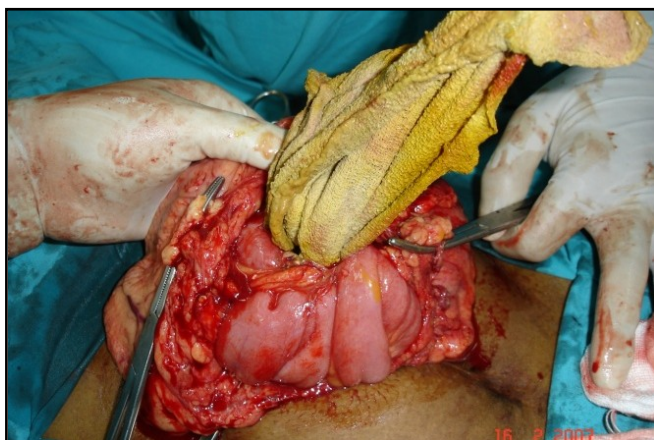

FIGURE IV: PERFORATIONS IN TWO LOOPS OF SMALL BOWEL AND SIGMOID COLON



patients presented with abdominal mass followed by intestinal obstruction in 43% patients. Discharging sinus from the surgical incision was the presenting complaint of only one patient. Another study from Pakistan also showed intestinal obstruction (58%), discharging sinus (42%), intra-abdominal abscess (17%), peritonitis (17%) and abdominal mass (8.33%) as the major presentations¹⁰. The largest review of literature on gossypibomas published so far has also suggested pain/irritation (42%), palpable mass (27%), and fever (12%) as the leading signs and symptoms, and adhesions (31%), abscess (24%), and fistula (20%) as the most common complications⁷.

The interval between the initial surgery when abdominal sponge is retained and the final surgery during which sponge is retrieved has been reported at 6.9 years (although it has marked variation), and depends upon the body's response to the foreign body⁷. In one unusual report, this time interval was 40 years¹². In our study the average interval was eight months while minimum and maximum periods were one week and 2 years respectively. Our results show that in all cases only abdominal sponge was retained and other types of cotton foreign bodies were not found. Literature has also quoted abdominal towel retained after open cholecystectomy and umbilical hernia repair¹³.

Awareness of the radiographic and sonologic appearance is required for early detection and diagnosis. There are reports in the literature of the appearance of a retained sponge on plain radiographs, CT scans, magnetic resonance images, and ultrasound^{7,9,10,14-18}. In our series CT scan was done in three cases, all of them showed typical image of cotton foreign body. Ultrasound alone was performed in three patients and in one patient it was done along with CT scan. Ultrasound suspected the cotton foreign body in one case. The contrast studies were done as a part of workup for intestinal obstruction but they did not give the diagnosis of retained abdominal sponge. Plain x-ray of abdomen was done in all cases, either alone or as a part of contrast image study. When the mass was situated in front of one of the psoas muscles, a characteristic feature was noted – there was a localized area of micro-air-bubbles, which was of almost same size as the mass. This finding was more clearly visible when there was no gas-filled intestine superimposing the mass. The micro-bubbles of entrapped air within the meshes of the cotton fibers of the sponge were very obvious when compared with the contra-lateral psoas muscle, where there was no sponge in front of it (Figure II). The air did not get absorbed because it was not in contact with any absorbing epithelium. In our series the sponge did not contain the radio-opaque filaments which are easily visible on x-ray examination and make the diagnosis of gossypiboma

easy.

Preoperative diagnosis is based on history of open abdominal surgery, physical examination findings and diagnostic imaging. In this study preoperative diagnosis of retained sponge was made in five (36%) cases. In another series of 14 cases from Baskant University of Turkey, preoperative diagnosis was also made in five patients¹⁹. Surgery is the mainstay in the treatment of abdominal gossypiboma but spontaneous passage through rectum has been reported¹. In our study open surgery was the only modality used for the retrieval of abdominal sponge and the post-operative recovery was uneventful in all patients and they were discharged after routine post-operative care. Eight percent mortality due to uncontrolled sepsis has been reported elsewhere⁸.

With the introduction of minimally invasive surgical procedures, the incidence of retained surgical sponges can be expected to fall. However, despite all the technical advancements of modern era, human errors are unavoidable and thus prevention of this complication may remain elusive⁷. The importance of repeated sponge count, once before opening and twice before closing the abdomen, is universally accepted. Standard sponges contain radio-opaque filament that are helpful in locating them. If a sponge is missing, a thorough search is required within the whole operation theatre and surgical site. If the search is unsuccessful, then a radiograph is mandatory. Paradoxically, in most cases of a retained sponge, the final count is apparently correct⁷. Perhaps the best way to prevent this complication is to carefully inspect the abdomen before closure even in the face of a correct count. Human factors and interpersonal issues have been studied in the prevention of medical mishaps and disasters^{7,20}. Research has shown that measures to improve team management and the quality of communication between team members have significant impact on human performance and especially in the operating theatres of teaching institutes, "interpersonal and communication issues are accountable for many inadequacies and blunders"^{7,21,22}.

Medicolegal, media and responsibility related issues: The media has always been very effective source of information and a tool for influencing the public opinion. Doctors are not considered a holy cow or a profession above the law, is another change; therefore law suits are filed against medical staff once the news of medical negligence and error was highlighted on media. Like any other issue which is taken up by the media and courts the blame game starts and every effort is made to put the responsibility on others. The law or guidelines directly addressing the retained swabs is sparse in our country. In the authors' view the best approach is "prevention is better

than cure". All efforts should be taken to avoid this complication and once this complication has occurred the best possible treatment should be provided to the patient, with audit of the system and team responsible should be carried out. With media one has to be very careful, try to avoid the media trial of the hospital or medical staff, provide the information which is based on facts, don't breach the confidentiality and other laws of medical ethics. Once the case is subjudice, avoid discussion on media as it is considered contempt of the court. In court the policy of "truth nothing but truth" should be followed. It is the court who will hold the responsible person. The author disagrees with the widely accepted believe that the operating surgeon is the only accused. In the author's view the whole surgical team and OT staff should share the responsibility.

CONCLUSION

Retained sponge is more common in obstetrical procedures performed in emergency. Postoperative abdominal mass and intestinal obstruction in a patient should raise a high index of suspicion for gossypiboma as these are common presenting features. Micro-air-bubbles in plain abdominal x-ray of post surgery patient appear to be a diagnostic feature of gossypiboma. CT scan is better than ultrasound or X-rays in identifying the retained sponge.

REFERENCE

1. Martin RA. Gossypiboma—"a surgeon's legacy" reported case and review of the literature. *Dis Colon Rectum* 2002;45:119-20.
2. Bani-Hani KE, Gharaiheh KA, Yaghan RJ. Retained surgical sponges (gossypiboma). *Asian J Surg* 2005;28(2):109-15.
3. Sheehan RE, Sheppard MN, Hansell DM. Retained intrathoracic surgical swab: CT appearances. *J Thorax Imaging* 2000;15:61-4.
4. Coskun M, Noyvat F, Agildere AM. CT features of a pericardial gossypiboma. *Euro Radiol* 1999;9:728-30.
5. Mathew JM, Rajshekhar V, Chandy MJ. MRI neurosurgical gossypiboma: report of two cases. *Neuroradiology* 1996;38:468-9.
6. Chater-Cure G, Fonnegra-Caballero A, Baldión-Elorza AM, Jiménez-Hakim E. [Gossypiboma in neurosurgery. Case report and literature review.] *Neurocirugia (Astur)* 2009;20(1):44-8, discussion 48-9.
7. Wan W, Le T, Riskin L, Macario A. Improving safety in the operating room: a systematic literature review of retained surgical sponges. *Curr Opin Anaesthesiol* 2009;22(2):207-14.
8. Mahalik SK, Puneet, Gupta SK, Khanna AK. Gos-

- syboma: intramural and transmural migration causing small bowel obstruction. ANZ J Surg 2008; 78(5):417-8.
9. Alis H, Soylu A, Dolay K, Kalayci M, Ciltas A. Surgical intervention may not always be required in gossypiboma with intraluminal migration. World J Gastroenterol 2007;13(48):6605-7.
 10. Moyle H, Hines OJ, McFadden DW. Gossypiboma of the abdomen. Arch Surg 1996;131:566-8.
 11. Ahmed G, Attiq-ur- Rehman S, Anjum MZ. Retained sponge after abdominal surgery. J Coll Physicians Surg Pak 2003;13(11):640-3.
 12. Szarf G, Mussi de Andrade TC, Nakano E, Szejnfeld D, Costa AS, Rymkiewicz E, et al. Forty-year-old intrathoracic gossypiboma after cardiac valve surgery. Circulation 2009;119(24):3142-3.
 13. Gencosmanoglu R, Inceoglu R. An unusual cause of small bowel obstruction: gossypiboma a case report. BMC Surg 2003;8:3-6.
 14. Roumen RMH, Weerdenburg HPG. MR features of a 24-year old gossypiboma: a case report. Acta Radiol 1998;39:176-8.
 15. Rappaport W, Haynes K. The retained surgical sponge following intra-abdominal surgery. Arch Surg 1990;125:405-7.
 16. Kim CK, Park BK, Ha H. Gossypiboma in abdomen and pelvis: MRI findings in four patients. AJR 2007;189:814-7.
 17. Sheward SE, Williams AG Jr, Mettler FA Jr, Lacey SR. CT appearance of a surgically retained towel (gossypiboma). J Comput Assist Tomogr 1986;10:343-5.
 18. Prasad HS, Krishnan A, Limdi J, Patankar T. Imaging features of gossypiboma; report of two cases. J Postgrad Med 1999;45:18-9.
 19. Yildirim S, Tarim A, Nursal TZ, Yildirim T, Caliskan K, Torer N, et al. Retained surgical sponge (gossypiboma) after intraabdominal or retroperitoneal surgery: 14 cases treated at a single centre. Langenbecks Arch Surg 2006;391(4):390-5.
 20. Reason JT. Understanding adverse events: the human factor. In: Vincent C, editor. Clinical risk management. London: BMJ publications. 1995. pp 9-30.
 21. Helmreich RL, Butler RA, Taggart WIZ. Behavioral markers in accidents and incidents: reference list. Austin, Texas, University of Texas, 1994.
 22. Helmreich RL, Schaefer HG. Team performance in the operating room. In: Bogner MS, editor. Human errors in medicine. Hillsdale, NJ: Erlbaum; 1994.



AUTHOR AFFILIATION:

Dr. Syed Asim Ali Jaffary

Associate Professor, Department of Surgery
Dow University of Health Sciences
Karachi, Sindh-Pakistan.

Dr. Shabnam Shamim Asim

Associate Professor
Department of Gynecology & Obstetrics
Karachi Medical & Dental College
Karachi, Sindh-Pakistan.

Dr. Saleha Anwar

Assistant Professor, Department of Radiology
Hamdard University, Karachi, Sindh-Pakistan.

Dr. M. Shahid Shamim (*Corresponding Author*)

Associate Professor, Department of Surgery
Dow University of Health Sciences
Karachi, Sindh-Pakistan.
Email: surgeonshamim@yahoo.com