

Forehead Flap for Reconstruction of Maxillofacial Region Defects

Mohammad Ilyas Shaikh, Fozia Rajput, Safia Khatoon, Muhammad Arif Shaikh

ABSTRACT

OBJECTIVES: To assess the efficacy and efficiency of forehead flap in reconstruction of maxillofacial region defects.

STUDY DESIGN: Descriptive study.

PLACE AND DURATION: Department of Oral and Maxillofacial Surgery King Edward Medical University/Mayo hospital Lahore, from November 2009 to June 2012.

METHODOLOGY: This study was carried out on 30 (Thirty) consecutive patients, of either sex, who required soft tissue reconstruction of maxillofacial region including oral cavity defects due to trauma, infection or after tumor ablative surgery. Follow up was done for four months and on every follow up visit, patients were questioned about the degree of satisfaction, with mouth opening and donor site aesthetics. Cosmetic deformity judged subjectively.

RESULTS: The axial pattern fascio-cutaneous flap, for the reconstruction of maxillofacial region with oral cavity defect, performed in 30 patients. Success rate of the flap was 100%, with only partial necrosis of the flap in 1 case. Subjective assessment of the donor site however showed suboptimal results with 30% (n-9) patients moderately satisfied and 20% patients (n-6) were unsatisfied.

CONCLUSION: Forehead flap is a reliable technique for reconstruction of maxillofacial region defects.

KEYWORDS: Superficial Temporal Artery, Forehead Flap, Pedicle, Local Flaps.

INTRODUCTION

Oral and maxillofacial surgeons frequently come across patients with maxillofacial defects of different severity, resulting from trauma or tumor resection. Defects of maxillofacial region are problematic not only for the patients, coping with physical and psychological sequelae of their condition, but also for the reconstructive surgeon, who has to evaluate treatment options to get the best possible results.¹

In majority of cases, maxillofacial defects are the result of infections, trauma, high velocity missile injuries, burns and tumor extirpations involving hard and soft tissues, causing psychological, physical and social stigma. When embarking upon reconstruction of maxillofacial defect, primary goal should be to preserve function and then cosmetics. Review of the literature revealed that with respect to quality of life, reconstruction is favored over obturation²⁻³. The reconstructive method chosen must be most appropriate for closure of the defect and therefore factors must taken into consideration are size of the defect, location of the defect and its proximity to important anatomic structures. Equally important factors are quality of the donor tissues, depth of the defect and age of the patient. Forehead flap is one of the commonly used pedicle flaps for reconstruction of moderate-size maxillofacial defects.⁴ It has been used for reconstruction of nasal defects dates back to early days of civilization as mentioned in the Hindu holy book "Susruta Veda" in 800

B.C.⁵ This is an axial pattern fascio-cutaneous flap supplied by superficial temporal vessels⁶ normally the anterior branch.⁷ Certainly it is quick, reasonably reliable & simple flap to raise.⁸ It is raised from tissues in the same anatomical region and therefore resemblance to the defect is maximum⁹. Its qualities include abundant tissue availability, which allows resurfacing of the entire nasal subunit, its excellent match in color and skin texture. Above all it has robust vascularity¹⁰ and low donor site morbidity. Forehead flap has the advantage of being locally available and has potential to resurface large nasal cutaneous defects⁹⁻¹⁰. This flap has consistent vascular anatomy, abundant blood supply & favorable arc of rotation. It can cover the soft tissue defects¹¹ by providing a thin muscle bulk as well as intact mucosal lining.¹² It can be advanced and rotated to cover the full thickness defects on the contra lateral hemi forehead, like a flag on its flag pole.¹³ This flap is long enough to reach the contra lateral anterior floor of mouth and may be raised bilaterally to provide a "VISOR" flap for anterior lip or chin reconstruction.¹⁴ Forehead flap is also useful to reconstruct the composite or full thickness cheek defects,¹⁵ skull base defects as well as nose¹⁶, eye brow & eye lid reconstruction^{17,18}. The exceptional reliability & usefulness of the flap in the maxillofacial area has preserved its role as a "lifeboat" flap.¹⁴

The surgeon is restricted by the complexity of the structures to be reconstructed, the availability of

tissue, compromise of the local vascular bed by radiation in tumor patients and the need for visual inspection of oncologic defects. Though other flaps e.g. platysma, trapezius, latissimusdorsi, myocutaneous flaps can also be used for facial reconstruction but these are not relied much, and donor site morbidity is high. Per-operatively surgical technique is not simpler as compared to forehead flap and there is a need to change patient's position. In the era of perforator flaps, use of this flap provides a more predictive outcome compared with musculocutaneous flaps that show atrophy over time and lead to a change in facial contours. It can be used in single stage surgery with less morbidity. Donor site defects are esthetically acceptable especially for older patients.

The primary objective of this study is to assess viability of forehead flap for the reconstruction of the maxillofacial region defect. This will also provide opportunity to document the capacity of this flap to restore function & physical form of the recipient site. The closure of the defect will improve the physical and psychological quality of the individual by eliminating self-consciousness regarding cosmetics, improving social life and interpersonal relationships.

METHODS

A prospective descriptive study carried out at Department of Oral and Maxillofacial Surgery, King Edward Medical University, Mayo Hospital Lahore, from November 2009 to June 2012. Thirty (30) Patients; with moderate-size defects (9-12 cm²) resulting after oncologic resection, infectious and post traumatic defects of oral cavity, mid-face and upper face region; aged between 35 to 59 years, of either gender were included.

Patients under radiation therapy to the forehead region, previous surgery or trauma to the forehead region and medically compromised patients who cannot tolerate general anesthesia were excluded. Written informed consent obtained from all patients/parents/attendants, for inclusion in surgical procedure and use of the data for research purpose. Data recorded on a specialized proforma.

Per-operatively, precise location of the superficial temporal artery was identified by palpation or with a pencil Doppler; to narrow the base of the flap precisely. The flap elevated in a sub-facial plane just superficial to the periosteum of the frontal bone. The flap rotated over the lateral zygomatic arch onto the face. However, when flap primarily designed for intraoral coverage, a tunnel between the donor site and the oral cavity created. Flap folded laterally and passed under the zygomatic arch, oral cavity entered through a tunnel made by a separate transverse cheek incision. After flap elevation for the face coverage, the flap was

tailored to fit the defect and sutured the defect. The donor site was skin grafted. Postoperatively, patient assessed for vitality of flap within first 12-24 hours. The vitality and health is based on color, margin necrosis and integrity of the flap. Flap sutures on face were removed on 6th post-operative day. Flap division if necessary was done after an average of 3 weeks. Follow-up was done for four months and on every follow-up visit, patients were questioned about the degree of satisfaction with speech and aesthetics. Hence the efficacy and efficiency is proved on the part of forehead flap reconstruction.

Efficacy

This flap can cover the maxillofacial defects cosmetically and can maintain the speech and mastication.

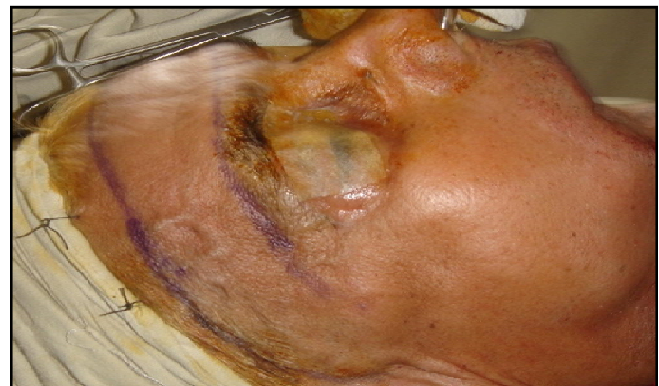Efficiency

The role of this flap is to provide a simple coverage which is resistant to infection and with least complications.

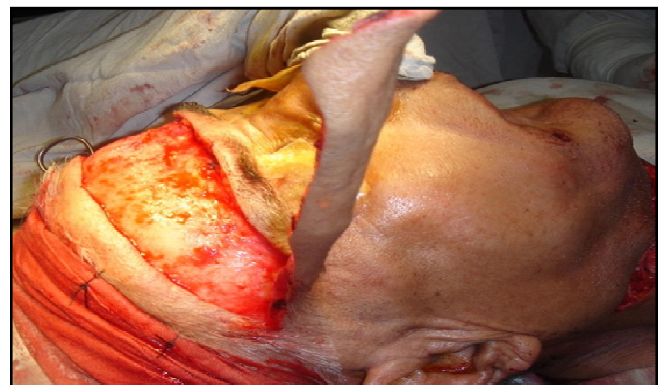
Results of the follow up of the patients conducted at after 1st week and after 2 months. The variables were noted and recorded for the purpose of detailed and critical objective evaluation.

For qualitative data e.g. outcome as complication the chi-square test, and for numerical data e.g. size of defect with duration of success t-test was applied. SPSS 17 was used to further evaluate the results.

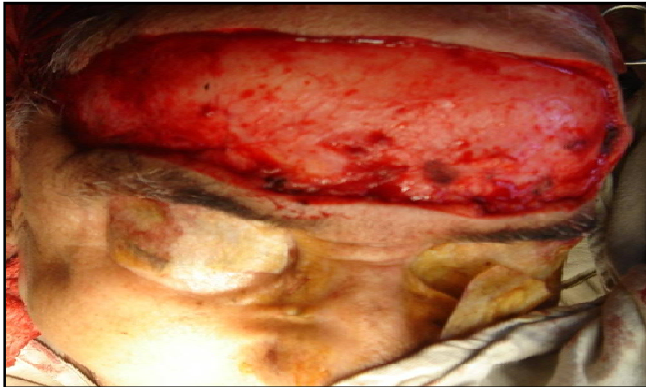
PEROPERATIVELY MARKING OF THE FLAP



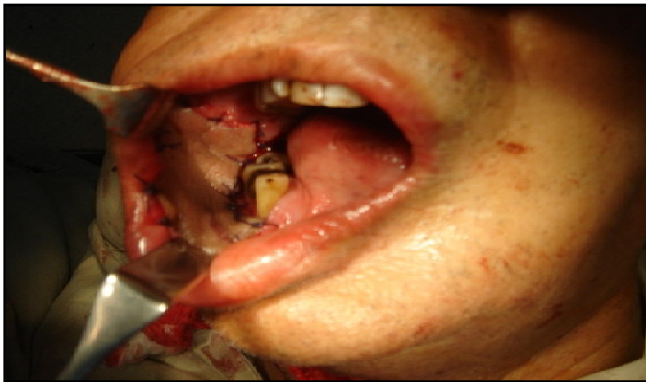
PEROPERATIVELY FLAP ELEVATION



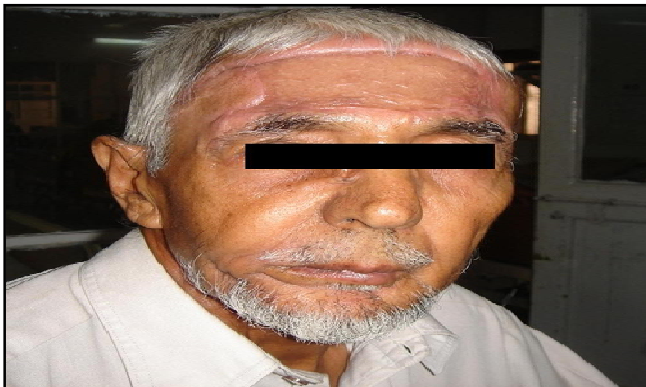PEROPERATIVELY DONORSITE DEFECT



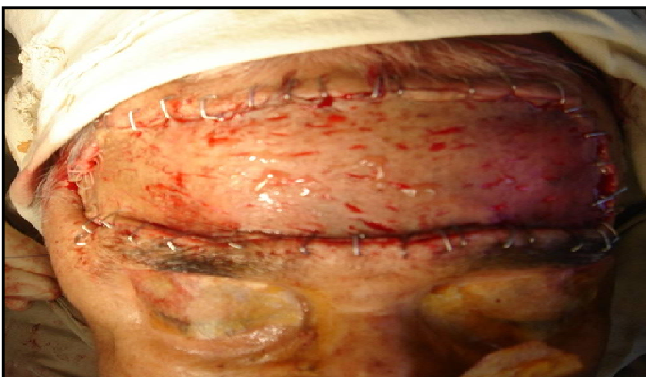
PEROPERATIVELY INTRAORAL FLAP INSETTING



POSTOPERATIVELY DONOR SITE AFTER ONE MONTH



PEROPERATIVELY SKIN GRAFTING ON DONOR SITE



RESULTS

Thirty patients who met the criteria were identified. Their ages ranged from 35 to 59 years, with 22 men and 8 women. Male gender predominates over female. Most of the patients were in their fourth decade of life (Table I). Out of 30 patients, 25 had oncological resection, and 2 had post traumatic defects including firearm injury and 3 patients were presented with post infectious defects. Among 2 post traumatic patients 1 patient with history of firearm injury and 1 with road traffic accident were included. Out of three patients with infections 1 patient had mucormycosis and 2 patients had osteomyelitis (Table II). Forehead flap reconstruction was done for intra oral moderate size (9-12 cm²) defects, these defects were mostly on the palate and buccal mucosa.

With regard to checking vitality of the flap, color of flap remained normal in 27 patients, only in two patients, it was seen slight bluish and in one patient, it was pale in immediate post operative period. Later, these flaps appeared normal with good vascularity, except one flap remained bluish and showed the partial necrosis at the end of 1st postoperative week (Table III). Suture dehiscence was observed in 6 patients. Out of 6 patients, 3 patients had due to the marginal necrosis and three patients had due to the post operative infection. Margins of the flap loss in 3 patient's including the one patient that had partial necrosis of the flap. Three patients developed the infection with in the 1st week of post-operative period.

Forehead flap is the local fasciocutaneous flap with the same color and texture to the local region. That's why it provides the very good aesthetic results in majority of patients. Because of its hairless property, it is an excellent tissue for reconstruction of the intra-oral defects. Out of 30 patients, 24 were fully satisfied with the flap aesthetic, 4 were moderately satisfied and 2 patients were unsatisfied with flap esthetics in their last follow-up visit.

Donor site aesthetic was much concern for all the patients, as it looks far from to the others and survived with social compromise. In two patients we did primary closure of the donor site and in 28 patients the defect was covered by split thickness skin grafts. In our study out of 30 patients, 15 were fully satisfied with the donor site esthetic, 9 were moderately satisfied and 6 patients were unsatisfied with donor site esthetics in their last follow-up visit.

Mouth opening may be altered where forehead flap has been used. It may be due to obstruction of coronoid process after the transposition of the forehead flap below the zygomatic arch, or damage to the temporalis and postoperative healing and fibrosis.

In this study out of 30 patients, 24 patients were fully satisfied with their mouth opening, 4 patients were

moderately satisfied and 2 patients were unsatisfied with their mouth opening in their last follow-up visit (Table IV).

TABLE I: DEMOGRAPHIC CHARACTERISTICS

Gender	No. of patients	%	Mean age & STD
Male	22	73.33	44 ±6.7096
Female	8	26.66	48±8.7722
Total	30	100.0	45±6.7154
P- value	< 0.01		

TABLE II: ETIOLOGIC FACTORS

Etiology	No. of Patients	%
Oncological resection	25	83.33
Post traumatic	2	6.67
Infections	3	10.0
Total	30	100.0
P – value	< 0.01	

TABLE III: POST-SURGICAL PROBLEMS

Color of flap	Dehiscence of sutures	Marginal necrosis	Infection
Bluish n-2(6.67%)	n-6 (20.0%)	n-3 (10.0%)	n-3 (10.0%)
Pale n-1 (3.3%)			
Normal n-27	Normal n-24	Normal n-27	Normal n-27
Total			
n-30 (100%)	n-30 (100%)	n-30 (100%)	n-30 (100%)

TABLE IV: TREATMENT OUTCOMES (DEGREE OF SATISFACTION)

Degree of satisfaction	Donor site Defect	Flap Esthetic	Mouth Opening
Fully satisfied	n-15 (50.0%)	n-24 (80.0%)	n-24 (80.0%)
Moderately satisfied	n-9 (30.0%)	n-4 (13.33%)	n-4 (13.33%)
Unsatisfied	n-6 (20.0%)	n-2 (6.67%)	n-2 (6.67%)
Total no of Patients	n-30 (100.0%)	n-30 (100.0%)	n-30 (100.0%)

DISCUSSION

The significance of reconstruction of maxillofacial region defects cannot be over emphasized in view of its unique position in a person's life. Reconstruction of facial defects is a challenge, which needs prompt creativity and innovation and demands strict adherence to the basic principles of reconstructive surgery and tissue transfer.

This study was carried out to see the viability of forehead flap after reconstruction of the maxillofacial region defects and to restore the function & physical form as close to nature as possible. As forehead flap is local flap of maxillofacial region and easily done in one stage surgery. While donor site defects are also acceptable after the skin grafting. This study determined the efficacy and efficiency of forehead flap in maxillofacial defects.

The first among these was color of flap. In our experience, the flap was very safe among 30 patients, 27 patients had normal color, which meant that these flaps had normal blood supply. However, in 2 patients, flap color was bluish and in 1 patient color of flap become pale. Out of these three flaps only one flap showed partial necrosis and two flaps appear normal after 1st postoperative week and the reconstruction was fairly good. The success rate of the flap was thus 97.77%. Only one flap culminated in partial necrosis, giving a 3.3% failure rate. This shows higher success rate of forehead flap in maxillofacial region reconstruction.

This research matches with the study of other researchers like Yan Z et al¹⁹ on forehead flap, used for the reconstruction of basicranial and nasifacial defects after tumor dissection on 14 patients, there was partial necrosis only in 2 patients. Current study is near to this study where the partial necrosis was in one patient.

McGregor IA⁶ used the forehead temporal flap in reconstruction of intra-oral cancer defects. In his study no flap loss was documented with 100% success rate. Another complication we came across with this flap was infection. In this series three cases were infected within 1st week of the postoperative period; two in the oral cavity and one in tunnel. Out of three, two patients were Diabetic. Appropriate antibiotics were advised and irrigation with normal saline, diluted hydrogen peroxide and control of blood glucose level salvaged it.

In the study of Cohen DJ et al²⁰, forehead flap was infected with abscess formation in the tunnel, used to transfer the forehead flap to the oral cavity for closure of oral defect. He recommended a more direct route with less dependent tunnel.

In the present study, we used Forehead flap as lining purpose as well as the coverage of the solid structure

like iliac bone or reconstruction plates for simultaneous reconstruction of mucosa and mandible. We experienced that Forehead flap has an excellent adaptability to the transplanted bed, along with near normal facial contour and tongue movements were not restricted.

Similarly in the study of Millard DRJr¹⁰, he used forehead flap for immediate coverage of an iliac bone graft for simultaneous reconstruction of mucosa and mandible following radical excision of jaw malignancy. In his study he found excellent results and the tongue movements were not restricted and facial mandibular contour was maintained in the patient who had immediate forehead procedure. Later, a successful functioning denture was fabricated for this patient.

In contrast to present research, Li QF²¹ and his associates used the forehead musculo-cutaneous flap by dividing it into muscular flap and the skin flap. Muscle flap was used for reconstruction of the septi bone and enveloped the silicon nasal frame, they used the skin flap to reconstruct the nose. 89% of the cases showed the coverage of exposed nasal frame work.

Although forehead flap is not providing very bulky tissue for reconstruction of through and through defects, but in our study we used this flap for lining as well as for external coverage by narrowing its pedicle. The distal flap was folded on it self for simultaneous restoration of mucosal lining. This procedure does not require any other flap or second donor site. Postoperative results were satisfactory.

Champion R²² in 1960 described this technique in his article. Through and through Cheek defects were reconstructed in single stage using a laterally based forehead flap. The author reports successful use of this technique in 12 patients.

Another option for reconstruction of full thickness defect is a double flap. In the present study, we used the forehead flap along with deltopectoral flaps in 2 cases and with pectoralis major myocutaneous flap in 3 cases. The simultaneous use of additional flap dependent upon size and extent of defect i.e. where the skin cover could not be provided by the bi-paddled pectoralis major flap, also in those defects whose portions were beyond the arc of rotation of the flap. Survival of double flaps and results of reconstruction remained satisfactory.

Wang Yet al²³, used double flap for external coverage as well as internal lining in cases of perforating defects. His study showed good results, in which 87 flaps survived completely or sub totally with a success rate of 96%, while total or large necrosis was seen in three flaps. These double flaps can provide excellent cover as internal lining and are well vascularized, hairless and colourmatched.

Although local flaps are very popular and useful flaps

because of their reliability, versatility and relative technical simplicity but every surgeon has its own experience and comments regarding these flaps. Shah AA et al¹¹ in his study did not favored the local flaps as it do not provide enough bulk to replace the lost tissue and there is an added disadvantage of stepped reconstruction with prolonged hospitalization and repeated admissions with its associated costs.

The biggest drawback of the forehead flap is the prominent residual forehead donor site scar due to full thickness skin graft. Although this is the universal rule of surgery that first we have to preserve the function then we must consider the element of cosmetics. Because of its exceptional reliability, versatility, relative technical simplicity and usefulness of the flap in the maxillofacial area has preserved its role as a "lifeboat" flap¹⁴, when other options failed.

However, the difficult reality is that many head and neck patients fall into lower end of socioeconomic spectrum and are uninsured so cannot afford the expenses of free tissue transfer, technically it is not feasible for every patient because of lack of resources, as well as cancer patients are usually from older age group, and are not very much concerned about their aesthetic. That's why this flap is still very much popular and the donor site defect can easily be camouflaged in the females by an appropriate hairstyle. In the present study donor site closure have been done with full thickness skin graft. For prevention of hyper pigmentation, sun blocks have been prescribed to avoid excessive sun exposure at least for first 4-6 months after reconstructive surgery.

CONCLUSION

Reconstruction with forehead flap in maxillofacial region defects provides natural building material precisely fitted to reconstruct maxillofacial defects to a condition as near to normal as possible. If a patient desires optimal aesthetic appearance with the best chance for function preservation, a staged forehead flap is the best option.

With this flap, immediate reconstruction with a reliable technique allowed the cancer surgeon to remove intraoral cancer with adequate margins and still obtain an acceptable functional result.

REFERENCES

1. Yetzer J, Fernandes R. Reconstruction of orbitomaxillary defects. *J Oral Maxillofac Surg.* 2013;71:398-409.
2. Rogers SN, Lowe D, McNally D, Brown JS, Vaughan ED. Health-related quality of life after maxillectomy: a comparison between prosthetic obstruction and free flap. *J Oral Maxillofac Surg.* 2003;61:174-81.

3. Genden EM, Okay D, Stepp MT, Rezaee RP, Mojica JS, Buchbinder D, Urken ML. Comparison of functional and quality-of-life outcomes in patients with and without palatomaxillary reconstruction: a preliminary report. Arch Otolaryngol Head Neck Surg. 2003;129:775-80.
4. Anastassov GE, Schwartz S, Rodriguez E. Buccinator myomucosal island flap for postablative maxillofacial reconstructions: a report of 4 cases. J Oral Maxillofac Surg. 2002;60:816-21.
5. Bhisagrana KKL, ed. SushrutaSambita. Calcutta, Bose, 1907-1916.
6. Mc Gregor A. The temporal flap in intra-oral cancer: Its use in repairing the post-excisional defect Br J Plast Surg. 1963;16:318-35.
7. Anastassov GE, Schwartz S, Rodriguez E. Buccinator myomucosal island flap for postablative maxillofacial reconstructions: a report of 4 cases. J Oral Maxillofac Surg. 2002; 60:816-21.
8. Price DL, Sherris DA, Bartley GB, Garrity JA. Forehead flap periorbital reconstruction. Arch Facial Plast Surg. 2004;6:222-7.
9. Sadhotra LP, Singh M, Raje R. Reconstruction of complete palatal defect with a forehead flap: A case report. Indian J Plast Surg. 2003;36:120-122.
10. Millard DR Jr. Total reconstructive rhinoplasty and a missing link. Plast Reconstr Surg. 1966;37:167-83
11. Shah AA, Malik WM. Head and neck reconstruction: a 3 years experience. Ann King Edward Med Coll. 1999; 5:19-21.
12. Warraich RA, Cheema SA. Head and neck reconstructive options for soft tissue defects.. Ann King Edward Med Coll. 2001; 7: 11-13.
13. Benito-Ruiz J, Monner J, Fontdevila J, Serra-Renom JM. Forehead flap. Br J Plast Surg. 2004; 57:270-2.
14. Booth PW. Reconstructive surgery- major flaps. In: Langdon JD, Patel MF eds. Operative Maxillofacial. Surgery. Cambridge: Chapman & Hall, 1998: 83-91.
15. Jiang F, Liao T, Zheng C, Wang H. One-stage reconstruction of large through-and-through defect of cheek with a combination of forehead skin flap and sternocleidomastoid island myocutaneous flap after cancer dissection. Zhongguo Xue Fu Chong Jian Wai Ke Za Zhi. 2005;19:815-7.
16. Naqvi SU, Hussain SI, Quadri S. Adenosquamous carcinoma of paranasal sinuses and Kartagener syndrome: an unusual combination. J Coll Physicians Surg Pak. 2014;24:S52-4.
17. Ganatra MA, Gooda MR. Study of Prevalence and Management of Basal Cell Carcinoma of the Nose. Pak J Surg. 2010; 26:80-83.
18. Brazzo BG, Saffra N. Dermatofibrosarcoma protuberans of the brow and eyelid. Ophthal Plast Reconstr Surg. 2004;20:332-4.
19. Yan Z, Fan Y, Ji W, Ye X, Shang J. One-stage reconstruction with the pedicle skin flap of forehead for defective tissue of head-neck tumors dissection. Lin Chuang Er Bi Yan Hou Ke Za Zhi. 1999;13:254-6.
20. Cohen DJ, Jones RF, Engrav LH. Sepsis of the cheek over a subcutaneous forehead flap. Plast Reconstr Surg. 1980;65:347-9.
21. Li QF, Lei H, Gu B, Liu K, Shen GX, Zheng DN, Zheng SW. Nasal reconstruction with forehead skin flap and muscle flap. Zhonghua Zheng Xing Wai Ke Za Zhi. 2004;20:351-3.
22. Champion R. Closure of full-thickness cheek loss by forehead flap. Br J Plast Surg. 1960;13:76-8.
23. Wang Y, Lan X, Li R. Reconstruction of perforating defects of the maxillofacial region with double flaps Zhonghua Zheng Xing Shao Shang Wai Ke Za Zhi. 1999;15:123-5.



AUTHOR AFFILIATION:

Dr. Mohammad Ilyas Shaikh

Assistant Professor
Department of Oral Surgery and Maxillofacial Surgery
Bibi Aseefa Dental College, Larkana, Sindh-Pakistan.

Dr. Fozia Rajput (*Corresponding Author*)

Assistant Professor, Department of Operative Dentistry
Liaquat University of Medical & Health Sciences
(LUMHS), Jamshoro, Sindh-Pakistan.
Email: rajputfozia@yahoo.com

Dr. Safia Khatoon

Assistant Professor, Department of Oral Pathology
Bibi Aseefa Dental College
Larkana, Sindh-Pakistan.

Dr. Muhammad Arif Shaikh

Assistant Professor, Department of Operative Dentistry
LUMHS, Jamshoro, Sindh-Pakistan.