

# Xanthogranulomatous Cholecystitis (XGC) – A Diagnostic Dilemma

Ahmer Akber Memon, Arshad Hussain Abro, Ahmed Hussain Pathan, Faisal Ghani Siddiqui, Abdul Aziz Laghari

## ABSTRACT

**INTRODUCTION:** Xanthogranulomatous cholecystitis (XGC) is an unusual form of chronic cholecystitis characterised by marked thickening of the gallbladder wall and accumulation of lipid laden macrophages. It is frequently misdiagnosed preoperatively with gallbladder carcinoma. The aim of this study was to assess the preoperative clinical and radiological characteristics, operative findings and histological features of patients with XGC based on the experience of a single institution. In addition a literature search was performed to identify previously reported cases.

**PATIENTS AND METHODS:** This retrospective study was conducted from January 2009 to December 2014. 1,989 consecutive patients who underwent elective cholecystectomy at the Surgical Unit-I, Liaquat University Hospital, Jamshoro, Pakistan were included in this study. Seventeen patients were identified to have XGC on histopathology.

**RESULTS:** Seventeen (0.8%) cases of XGC were identified in 1,989 cholecystectomy specimens performed. The female to male ratio was 7.5:1. The average age in our series was 51.6 (range from 18 to 77 years). Two (11.7%) cases, suspected of malignancy during preoperative work-up, were reported as XGC on histopathology.

**CONCLUSION:** Preoperative differentiation between XGC and carcinoma of the gallbladder remains challenging due to similarities in clinical presentation, radiological and operative findings. In view of this there should be a low threshold for conversion from a laparoscopic to an open procedure.

**KEYWORDS:** Xanthogranulomatous, Cholecystitis, Carcinoma.

*This article may be cited as:* Memon AA, Abro AH, Pathan AH, Siddiqui FG, Laghari AA. Xanthogranulomatous Cholecystitis (XGC) – A Diagnostic Dilemma. J Liaquat Uni Med Health Sci. 2015;14(03):115-9.

## INTRODUCTION

Xanthogranulomatous cholecystitis (XGC), first described as a pathological condition in 1981 by Goodman and Ishak<sup>1</sup>, is an unusual variant of cholecystitis, characterized by destructive inflammatory process, poorly demarcated firm yellow masses, accumulation of severe proliferative fibrosis, and foamy histiocytes within the gallbladder wall.<sup>2</sup> It typically presents symptoms, either of acute cholecystitis, nausea and vomiting or of chronic cholecystitis with dull right hypochondrial pain; at times, right upper quadrant mass may be palpable, as the inflammation extends into adjacent structures; paradoxically, and not uncommonly, clinical and radiologic findings may mimic gallbladder carcinoma.<sup>3,4</sup>

Despite advances in diagnostic techniques, preoperative and intra-operative diagnosis of XGC remains a challenge.<sup>5</sup> Correct diagnosis of XGC is important for several reasons; inaccurate preoperative diagnosis may cause difficult surgery, specially laparoscopy with high frequency of complications. Laparoscopic chole-

ctectomy is often unsuccessful, with a high conversion rate.<sup>6,7</sup> The correct preoperative diagnosis of this complicating disease therefore remains paramount for the surgeon.

We share our experience of the clinical, radiological, operative and histological features exclusive of XGC. In addition, a literature search was performed to identify previously reported cases.

## PATIENTS AND MATERIAL

Clinical record of 1,989 patients who had undergone cholecystectomy between January 2009 and December 2014 at Surgical Unit-I, Liaquat University Hospital, Jamshoro, Pakistan were reviewed retrospectively. Routine biochemical tests, ultrasound abdomen were done in all patients while, in selected patients, CT scan of abdomen and ERCP were also carried out. Of the Total 1,989 gallbladder specimens sent for histopathology, seventeen patients were identified to have XGC on histology. The criteria used for diagnosis of XGC included: focal or diffuse mural affection with the

presence of histiocytes, cholesterol deposits and lipids; giant multinucleated cells of the type that react to foreign bodies or of the Touton type; cells that phagocytose lipids and bile pigments, forming xanthomatous cells; and the presence of cells of acute and chronic inflammation. The clinical presentations, preoperative investigations, intra-operative findings, postoperative complications and hospital stay were analyzed. Statistical analysis was performed by SPSS statistical software (version 13.0).

**RESULTS**

Seventeen (0.8%) cases of XGC were identified in 1,989 cholecystectomies performed in our unit during a period of 5 years. There were fifteen females and two males with a female to male ratio of 7.5:1. The average age in our series was 51.6 (range from 18 to 77) years. The most common presentation was chronic pain in the right upper quadrant. Other presenting symptoms are summarized in Table I. Two patients presented with jaundice. Preoperative ultrasound reported thick walled gallbladder in all seventeen cases (100%). The sonographic findings of these cases are depicted in Table II.

In 4 patients, in whom preoperative ultrasound roused suspicion of gallbladder carcinoma, those having mass right hypochondrium or presented with feature suggestive of obstructed jaundice, the computerized tomography was performed. CT revealed thick walled gallbladder in all 4 cases (Figure I). Two patients (11.7%) were reported to have carcinoma gallbladder; were found having XGC on histopathology (Figure II). The other findings of tomography reported are shown in Table III. Two patients in this series underwent preoperative Endoscopic Retrograde Cholangiopancreatography (ERCP) either due to suspected CBD stone and/or dilated CBD. Stones were retrieved in one case. The other case was reported to have stricture of lower end of CBD. Sphincterotomy and stenting was done in this case before cholecystectomy undertaken. Among 17 patients, Laparoscopic cholecystectomy was done in 9 (53%) patients but had to be converted to open surgery in 7 (78%) patients due to the obscure anatomy, presence of dense fibrosis with extensive local inflammation with adhesions to surrounding organs and concerns for, possible coexistent malignancy. Eight (47%) patients underwent open cholecystectomy due to anticipation of difficult surgery. Perioperatively, XGC associated with Mirizzi's syndrome and chylolystocolonic fistula were seen in two patients while one patient had mass secondary to dense adhesions. The findings on operation are depicted in table IV. Three patients (17.6%) developed postoperative complications. Two patients (11.8%) developed postoperative wound infection. Staphylococcus aureus

and E.coli were the microorganisms identified on culture. All wounds were treated with opening up of stitches and antibiotics. One patient (5.8%) developed bile leakage, which responded to conservative treatment.

**TABLE I: CLINICAL PRESENTATION (n=17)**

Signs/symptoms	Number	%
Chronic RUQ pain	11	64.7
Obstructive jaundice	2	11.7
RUQ mass	1	5.8

**TABLE II: ULTRASONOGRAPHIC FINDINGS (n=7)**

Findings	Number	%
Thick walled gallbladder	17	100
Gallstones		
• Single	10	59
• Multiple	07	41
Distended gallbladder	03	17.6
Dilated CBD	01	5.8
CBD stone	01	5.8
Mass in gallbladder	01	5.8

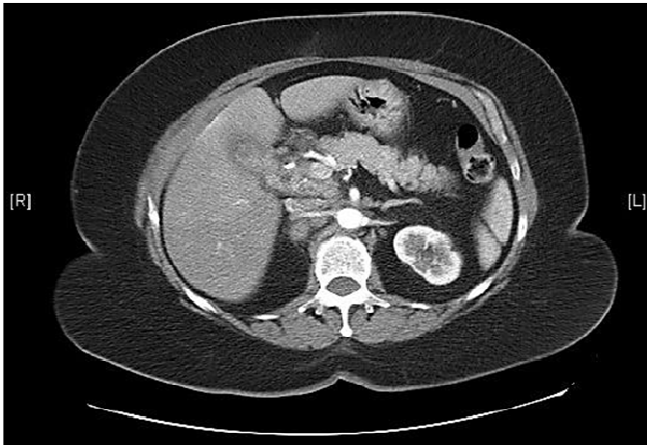
**TABLE III: XANTHOGANULOMATOUS CHOLECYSTITIS: COMPUTED TOMOGRAPHIC (CT) FINDINGS**

Findings	Number (n=4)	%
Thickened wall	04	100
Cholelithiasis	04	100
Dilatation of CBD	02	50
Low attenuation	02	50
Soft tissue mass consistent with enlarged lymph node near neck of GB	02	50

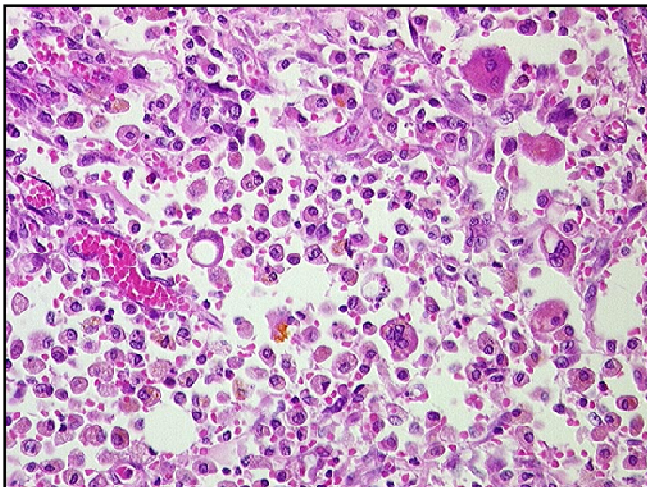
**TABLE IV: OPERATIVE FINDINGS (n=17)**

Findings	Number	%
Thick walled GB	17	100
Adhesions with		
• Omentum	7	41
• Duodenum	4	23.5
• Colon	2	11.8
Hard, fixed GB	4	23.5
Indistinct anatomy of the Calot's triangle	11	64.7

**FIGURE I: CT SCAN SHOWING A THICK-WALLED GALLBLADDER**



**FIGURE II: SHOWING GALLBLADDER HISTOPATHOLOGY**



## DISCUSSION

XGC is an uncommon entity; it represents about 0.7–13.2 % of all cholecystectomies performed for benign diseases of the gallbladder.<sup>8-11</sup> We found prevalence of 0.8% (17/1,989). Though XGC affects men and women equally<sup>12</sup>, Gandrapu et al. report a slight female preponderance with a mean age of 60.2 years<sup>9</sup>. In our series, a stark gender difference was observed with a female to male ratio of 7.5:1. The mean age was 51.6 years.

Chronic upper abdominal pain of variable duration was the main presenting complaint in our series. Three patients (17.6%) had symptoms suggestive of acute cholecystitis and cholangitis. Two patients (11.7%) had obstructive jaundice at the time of admission; jaundice in XGC is usually secondary to stones in the common bile duct, associated Mirizzi's syn-

drome or an underlying gallbladder carcinoma<sup>13</sup>; Xanthogranuloma Cholechochitis secondary to inflammatory involvement of biliary tree is a rare cause of biliary stricture leading to obstructive jaundice. In our series, one patient with jaundice was found to have CBD stones while the other had stricture of lower end of CBD. Case reports showing xanthogranulomatous strictures of the common bile duct document such complications.<sup>14,15</sup> We encountered Mirizzi's syndrome and cystocolonic fistula in two patients, respectively. Fistulae, in XGC, result secondary to the spread of inflammatory process to adjoining structures.

All 17 patients in our series were identified to have single or multiple gallstones on ultrasound and confirmed on subsequent cholecystectomy. This was comparable to similar studies where 84 to 100 per cent cases of XGC were associated with gall stone disease.<sup>16-18</sup> Thickening of gallbladder wall seen on radiological investigations is a global finding in patients with XGC. Thick walled gallbladder was reported on ultrasound in all 17 patients in our series. In one case, a complex mass, suggestive of malignancy, was reported on ultrasound.

In our series, CT scan was done in four patients with specific indications such as obstructive jaundice, palpable mass, and suspicion of tumor. CT revealed thick walled gallbladder in all four cases. The tomographic findings suggestive of XGC include a hypodense band in the gallbladder with contrast enhancement of the mucosa, the latter representing preservation of epithelial layer favoring XGC over malignancy.<sup>19</sup> Non-visualization of cystic duct on computed tomography after IV infusion cholangiography scan has been reported to be the most important sign of XGC.<sup>15</sup> CT scan was non-specific in our series and did not show any signs suggestive of Xanthogranuloma.

Preoperative diagnosis of XGC is possible through contrast-enhanced ultrasound sonography and fluorine-18 fluorodeoxyglucose positron emission tomography (FDG-PET). The former reveals homogeneously enhanced gallbladder wall in the early vascular phase as an indicator of XGC.

At operation, indistinct anatomy was reported in 11 out of 17 cases (64.7%). This was due to dense adhesions between the thick-walled gallbladder and adjoining structures mimicking carcinoma. Four cases in our series presented with stony hard and fixed gallbladders giving an impression of carcinoma. Timely frozen-section helped identify benign pathology in all four cases presenting with "infiltration" into surrounding

organs. Difficulty in dissection due to dense adhesions and fixity was the cause of conversion from laparoscopic to open cholecystectomy in 7 out of 17 patients, giving a conversion rate of 41.2%. This conversion rate is similar to the rate encountered by Srinivas et al. who report eleven conversions in 24 attempted cases with a conversion rate of 46 per cent.<sup>9</sup> We performed total cholecystectomy in fifteen cases (88.2%); in two cases, extensive fibrosis, and altered anatomy resulted in partial cholecystectomy.

Three patients (17.6 %) developed postoperative complications, a rate comparable to other similar studies.<sup>9</sup> Postoperative wound infection was seen in two patients (11.8 %); *Staphylococcus aureus* and *E.coli* were the major organisms found on culture. All wounds were treated with opening up of stitches and I.V cephalosporin and amikacin and in this series, one patient developed bile leakage. The patient responded to conservative management with stoppage of leakage on thirteenth postoperative day. The average hospital stay in our series ranged from five to thirty six days.

### CONCLUSION

Xanthogranulomatous cholecystitis causes a diagnostic dilemma, both pre- and per-operatively. Routine preoperative investigations often fail to differentiate this benign condition from carcinoma gallbladder. Early resort to on table frozen section is the only reliable means for differentiating XGC and carcinoma. Although XGC is a histological diagnosis, a high suspicion on part of the surgeon should incite them to quick conversion to open cholecystectomy.

### REFERENCES

1. Goodman ZD, Ishak KG. Xanthogranulomatous cholecystitis. *Am J Surg Pathol.* 1981;5(7):653-9.
2. Elwood DR. Cholecystitis. *Surg Clin North Am.* 2008 Dec;88(6):1241-52.
3. Yoshida J, Chijiwa K, Shimura H, Yamaguchi K, Kinukawa N, Honda H, et al. Xanthogranulomatous cholecystitis versus gallbladder cancer: clinical differentiating factors. *Am Surg.* 1997 Apr;63(4):367-71.
4. Ghosh M, Sakhuja P, Agarwal AK. Xanthogranulomatous cholecystitis: a premalignant condition? *Hepatobiliary Pancreat Dis Int.* 2011 Apr;10(2):179-84.
5. Yildirim M, Oztekin O, Akdamar F, Yakan S, Postaci H. Xanthogranulomatous cholecystitis remains a challenge in medical practice: experience in 24 case. *Radiol Oncol.* 2009;43(2):76-83.
6. Srikanth G, Kumar A, Khare R, Siddappa L, Gupta A, Sikora SS, et al. Should laparoscopic cholecystectomy be performed in patients with thick-walled gallbladder? *J Hepatobiliary Pancreat Surg.* 2004;11(1):40-4.
7. Guzman-Valdivia G. Xanthogranulomatous cholecystitis in laparoscopic surgery. *J Gastrointest Surg.* 2005 Apr;9(4):494-7.
8. Karabulut Z, Besim H, Hamamci O, Bostanoglu S, Korkmaz A. Xanthogranulomatous cholecystitis. Retrospective analysis of 12 cases. *Acta Chir Belg.* 2003 Jun;103(3):297-9.
9. Srinivas GN, Sinha S, Ryley N, Houghton PW. Perfidious gallbladders - a diagnostic dilemma with xanthogranulomatous cholecystitis. *Ann R Coll Surg Engl.* 2007 Mar;89(2):168-72.
10. Reed A, Ryan C, Schwartz SI. Xanthogranulomatous cholecystitis. *J Am Coll Surg.* 1994 Aug;179(2):249-52.
11. Houston JP, Collins MC, Cameron I, Reed MW, Parsons MA, Roberts KM. Xanthogranulomatous cholecystitis. *Br J Surg.* 1994 Jul;81(7):1030-2.
12. Eriguchi N, Aoyagi S, Tamae T, Kanazawa N, Nagashima J, Nishimura K, et al. Xanthogranulomatous cholecystitis. *Kurume Med J.* 2001;48(3):219-21.
13. Corvera CU, Blumgart LH, Darvishian F, Klimstra DS, DeMatteo R, Fong Y, et al. Clinical and pathologic features of proximal biliary strictures masquerading as hilar cholangiocarcinoma. *J Am Coll Surg.* 2005 Dec;201(6):862-9.
14. Guzman-Valdivia G. Xanthogranulomatous cholecystitis: 15 years' experience. *World J Surg.* 2004 Mar;28(3):254-7.
15. Kwon AH, Matsui Y, Uemura Y. Surgical procedures and histopathologic findings for patients with xanthogranulomatous cholecystitis. *J Am Coll Surg.* 2004 Aug;199(2):204-10.
16. Goldar-Najafi A, Khettry U. Xanthogranulomatous choledochitis: a previously undescribed mass lesion of the hepatobiliary and ampullary region. *Semin Liver Dis.* 2003 Feb;23(1):101-6.
17. Pantanowitz L, Goldar-Najafi A, Nasser I. Xanthogranulomatous choledochitis mimicking cholangiocarcinoma. *Pathol Int.* 2004 Mar;54(3):213-5.

18. Pottakkat B, Saxena R, Nag HH, Kumari N, Krishnani N. Ampullary xanthogranulomatous inflammation mimicking periampullary cancer: report of a case. JOP. 2006;7(2):222-5.
19. Shuto R, Kiyosue H, Komatsu E, Matsumoto S, Kawano K, Kondo Y, et al. CT and MR imaging findings of xanthogranulomatous cholecystitis: correlation with pathologic findings. Eur Radiol. 2004 Mar;14(3):440-6.



*AUTHOR AFFILIATION:*

**Dr. Ahmer Akber Memon**

Department of Surgery  
Liaquat University of Medical & Health Sciences  
(LUMHS), Jamshoro, Sindh-Pakistan.

**Dr. Arshad Hussain Abro** (*Corresponding Author*)

Assistant Professor, Department of Surgery  
Liaquat University of Medical & Health Sciences  
LUMHS, Jamshoro, Sindh-Pakistan.  
Email: drahabro@hotmail.com

**Dr. Ahmed Hussain Pathan**

Assistant Professor, Department of Surgery  
LUMHS, Jamshoro, Sindh-Pakistan.

**Prof. Faisal Ghani Siddiqui**

Professor, Department of Surgery  
LUMHS, Jamshoro, Sindh-Pakistan.

**Prof. Abdul Aziz Laghari**

Professor, Department of Surgery  
LUMHS, Jamshoro, Sindh-Pakistan.