

Morphology of Root Canals in Mandibular Third Molar in Pakistani Population

Muhammad Rauf Ahmed

ABSTRACT

OBJECTIVE: To determine the number and morphology of root canals in mandibular third molar teeth in Pakistani population.

METHODS: This prospective cross-sectional study was conducted in department of dentistry, Faisalabad Medical University Faisalabad. Sixty(60) patients with irreversible pulpitis in erupted mandibular third molars having age 25-60 years were selected. A total of seventy (70) teeth were evaluated from 1-Jan-2017 to 31-Aug-2017. Periapical x-rays were done in every patient to analyze the number and morphology of root canals. Root canals (RC) were prepared and filling was done using cold lateral compaction technique and restoration was done. After restoration, again x-rays was taken to confirm any missing root canal.

RESULTS: The mean age of study patients was 43.2 \pm 6.3 years. There were 37 (61.7%) males and 23 (38.3%) female patients. Regarding number of root canals, 3 root canals were diagnosed in 43 (61.43%) teeth, 4 root canals in 16 (22.86%) teeth and 2 root canals in 8 (11.43%) teeth. Regarding classification of root canals types, type I root canals in 37 (52.86%) teeth, type II in 13 (18.57%) teeth, and type III in 8 (11.43%) teeth.

CONCLUSION: Present study results showed that 3 and 4 root canals are most common in our population.

KEYWORDS: Endodontic, mandibular third molar, root canals.

This article may be cited as: Ahmed MR. Morphology of Root Canals in Mandibular Third Molar in Pakistani Population. J Liaquat Uni Med Health Sci. 2018;17(02):109-12.
doi: 10.22442/jlumhs.181720561

INTRODUCTION

Knowledge regarding the anatomy of root canal is of prime importance for dentist for successful treatment of root canals. Pre-procedural knowledge regarding variations in and number of root canals helps in timely management and accurate treatment which in otherwise may results in complications during the procedure^{1,2}.

The primary purpose of root canal treatment is complete cleaning of the pulp space using chemicals and mechanical methods, then filling of the canal with filling materials and coronal seals³. It is very important to locate and fill all root canals. Missing root canals are the leading factor of failure of orthodontic procedures. Pre-op radiographs, digital X-rays, contrast x-rays, and micro-computed tomography are the routinely used methods of evaluation of morphology and variations of root canals^{4,5}.

Nowadays, retention of teeth especially third molars rather extraction is most common especially on the demands of the patients. So many patients having problems with teeth are now referred for orthodontic procedures instead of extraction^{6,7}. Successful RCT is mandatory to prevent extraction⁸. Many investigators have published the morphology of roots canals in

mandibular third molars. There is a huge variation in morphology of root canals in different studies.⁹⁻¹¹ This variation may be due to ethnicity of the studied populations. The aim of present study is to determine the number and morphology of root canals in mandibular third molar teeth.

METHODOLOGY

This prospective cross-sectional study was conducted in department of dentistry, Faisalabad Medical University Faisalabad. Non-probability purposive sampling was used for data collection. Sixty (60) patients with irreversible pulpitis in erupted mandibular third molars having age 25-60 years were selected in present study. Mentally retarded patients, patients with limited mouth opening and those having grossly carious third molars were excluded from study. A total of seventy (70) teeth were evaluated from 1-Jan-2017 to 31-Aug-2017. This sample size was calculated by taking prevalence of two root canals in 1.2% teeth, at $\alpha = 0.05$ the calculated sample size was 32 teeth. We included the double number of teeth in present study to make the results of present study more reliable. Informed consent from patients and ethical approval from IRB board was taken.

Plain Periapical x-rays were done in every patient to analyze the number and morphology of root canals. For obtaining direct access to the epical foramina, roof of the pulp chamber was removed maximum. Tapering fissure bur was used to get initial penetration of to the pulp chamber. After getting access, safe tipped fissure bur was used to remove the roof of the pulp chamber. After that all carious portion or caries was removed, canal orifices were located using endodontic explorer. Number of root canals was confirmed by placing files in all orifices. After identification of canals, files were placed in each canal and x-rays with parallel technique along with mesial shift technique and the numbers of canals were verified.

Canals were prepared and obtunded with lateral compaction. Permanent restorations were placed and another x-rays were taken for each tooth to confirm number of canals and quality of obturation. X-rays were taken using parallel and mesial shift angles to reconfirm the number of canals. Filling of the root canals was done using cold lateral compaction technique and restoration was done. After completing the whole procedure, x-rays was done again to confirm any missing root canal. Vertucci criteria were used for classification of the configuration of root canals.

SPSS version 23 was used to calculate frequency and percentages of gender, number of root canals and morphology of canals.

RESULTS

The mean age of study patients was 43.2 +6.3 years. There were 37 (61.7%) males and 23 (38.3%) female patients. Regarding number of root canals, 3 root canals were diagnosed in 43 (61.43%) teeth, 4 root canals were diagnosed in 16 (22.86%) teeth and 2 root canals were diagnosed in 8 (11.43%) teeth (Figure I).

Regarding classification of root canals types, type I root canals were identified in 37 (52.86%) teeth, type II root canals were identified in 13 (18.57%) teeth, type III in 8 (11.43%) teeth. Detailed morphology of root canals is given in Figure II.

DISCUSSION

There is a huge variation in the anatomy and morphology of mandibular third molar teeth¹². Studies have found a big impact of racism and genetics on these variations in root canals¹³, so it is necessary to determine the variations in number and morphology of root canals among different populations. For this many studies on the evaluation of root canals have been done in different regions of the world. In present study, we determined the number of root canals and

FIGURE I: FREQUENCY OF NUMBER OF ROOT CANALS

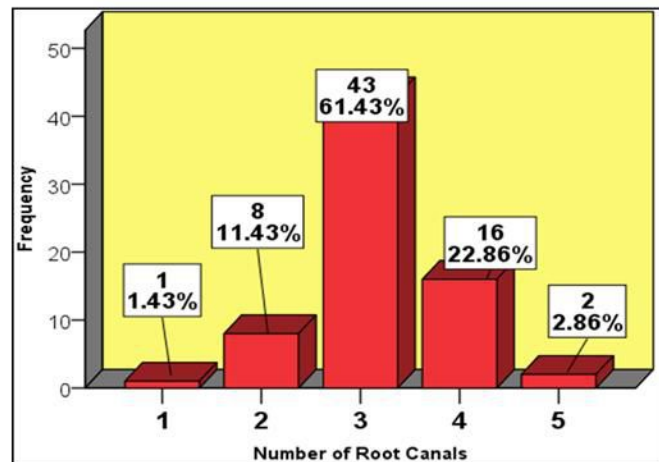
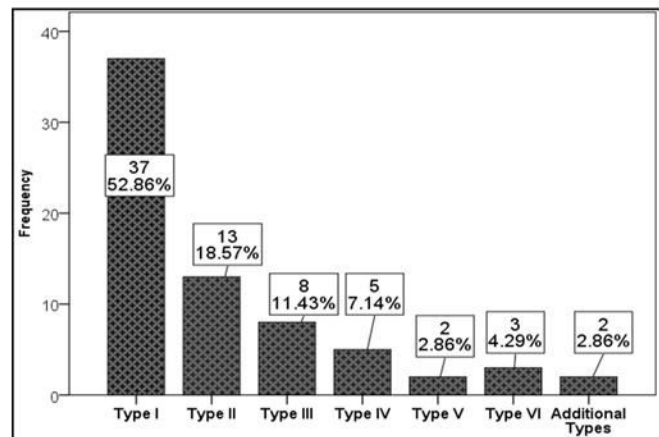


FIGURE II: CLASSIFICATION OF ROOT CANALS PER TEETH (VERTUCCI CLASSIFICATION)



their morphological classification in population of South Punjab Pakistan.

Failure to locate and treat all the root canals in a tooth is a major factor of failure of root canal treatment¹⁴, so it's necessary for the dentist to thoroughly understand the number and morphology of these canals before treatment. Each tooth regardless of what it is should be fully investigated using x-rays or other tests modalities to detect these possible disparities. Allen et al¹⁵ conducted a study on 1300 teeth to detect possible causes of failure of root canal treatment and found that missing root canals are responsible for 8.8% cases of failure. While another research found missing canals as risk factor of failure in 42.0% of studied teeth of patients¹⁶.

In present study, number of 3 root canals was identified in 61.43% teeth followed by 4 canals in 22.86 % teeth and then 2 in 11.43 % cases and 5 root canals in 2.86 % cases. Somasundaram et al⁵ found 3 root canals in 64.3% cases, 2 in 19.9% cases, 1 in

5.8% cases and 5 root canals in 1.2% cases. These authors used cone beam computed tomography for analysis of morphology of teeth while we used Periapical radiographs. Khan et al¹⁷ found 3 canals in 75.0% teeth, 2 in 18.3% teeth and 4 in 5.0% teeth. Cosic et al¹⁸ from Croatia found 3 root canals in 83.9% teeth, 2 in 5.4%, 1 canal in 8.9% teeth and 4 root canals in 8.9% teeth. Sert et al¹⁹ from Turkey found 3 root canals in 5.4% teeth, 2 canals in 69.5% teeth, 1 in 24.9% teeth and 4 root canals in 0.3% teeth. Park et al⁹ from Korea found 3 root canals in 1.9% teeth, 2 canals in 56.5% and 1 root canal in 41.6%. Ahmad et al²⁰ from Qatar found 4 root canals in 45.7% teeth, 4 canals in 8.6% teeth, 2 canals in 38.6% and 1 root canal in 7.1% teeth.

Regarding morphology of root canals, type I root canal was found in 52.86% teeth, type II canals in 18.57% cases and type III root canals in 11.43% teeth, type IV root canals 7.14% teeth, type V root canals in 4.29% cases, type V and additional types in 2.86% cases. Zafar et al²¹ from India found type I root canals in 41.2% teeth, type II in 17.6% teeth, type III & IV in 11.7% teeth. Mukhaimer et al²² from Palestine found type I root canals in 57.5% teeth, type II in 22.5% teeth, type III in 10.6% teeth, type IV in 8.1% teeth, type V in 1.3% and additional types in 3.2% teeth. Kuzekanani et al²³ from Iran found type I canals in 39.3% teeth, type II in 12.7%, type III in 10.0%, type IV in 1.33% and type V in 4.0% studied teeth.

Published literature has documented huge variations in the number and morphology of root canals in population from different countries. Accurate knowledge about anatomy and morphology of root canals is a key of success of root canal treatment.

The limitation of current study was that we used simple x-rays for evaluation of root canal it gives only two dimensional images and has low accuracy as compared to the tomography and cleaning techniques. However it is readily available and the results are not too much different when compared to the modern techniques so it can be used as a reliable tool for determining the morphology of root canals.

CONCLUSION

Results of present study showed that 3 and 4 root canals are most common in South Punjab Pakistani population. Type I, type II and type III root canals (according to vertucci classification) are common variants in mandibular third molar.

REFERENCES

1. Cantatore G, Berutti E, Castellucci A. Missed anatomy: frequency and clinical impact. *Endodontic Topics*. 2006; 15(1):3-31.
2. Torabinejad M, Fouad A, Walton RE.

- Endodontics: Principles and practice 5th eds; Elsevier Health Sciences: 2014.
3. Ingle JI. *Ingle's endodontics 6*: PMPH-USA; 2008. ISBN 1550093339.
4. Fisher DE, Ingersoll N, Bucher JF. Anatomy of the pulpal canal: three-dimensional visualization. *J Endod*. 1975; 1(1):22-5. doi: 10.1016/S0099-2399(75)80245-7
5. Somasundaram P, Rawtiya M, Wadhvani S, Uthappa R, Shivagange V, Khan S. Retrospective Study of Root Canal Configurations of Mandibular Third Molars Using CBCT-Part-II. *J Clin Diag Res*. 2017; 11(6):ZC55-ZC59. doi: 10.7860/JCDR/2017/20153.10072
6. Silberman A, Heilborn C, Cohenca N. Endodontic therapy of a mandibular third molar with 5 canals: a case report. *Quintessence Int*. 2009; 40(6): 453-5.
7. Sinha DJ, Sinha AA. An endodontic management of mandibular third molar with five root canals. *Saudi Endod J*. 2014; 4(1):36-9.
8. Ahmed HMA. Management of third molar teeth from an endodontic perspective. *Eur J Gen Dent*. 2012; 1(3):148-60.
9. Park JB, Kim N, Park S, Kim Y, Ko Y. Evaluation of root anatomy of permanent mandibular premolars and molars in a Korean population with cone-beam computed tomography. *Eur J Dent*. 2013;7(1):94-101.
10. Rawtiya M, Somasundaram P, Wadhvani S, Munuga S, Agarwal M, Sethi P. Retrospective study of root canal configurations of maxillary third molars in Central India population using cone beam computed tomography Part-I. *Eur J Dent*. 2016; 10(1):97-102.
11. Sidow SJ, West LA, Liewehr FR, Loushine RJ. Root canal morphology of human maxillary and mandibular third molars. *J Endod*. 2000; 26(11):675-8. doi: 10.1097/00004770-200011000-00011
12. Faramarzi F, Shahriari S, Shokri A, Vossoghi M, Yaghoobi G. Radiographic evaluation of root and canal morphologies of third molar teeth in Iranian population. *Avicenna J Dent Res*. 2013; 5(1):e21102.
13. Ahmed HA, Abu-bakr NH, Yahia NA, Ibrahim YE. Root and canal morphology of permanent mandibular molars in a Sudanese population. *Int Endod J*. 2007; 40(10):766-71.
14. Vertucci FJ. Root canal morphology and its relationship to endodontic procedures. *Endod Topics*. 2005; 10(1):3-29.
15. Allen RK, Newton CW, Brown CE Jr. A statistical analysis of surgical and nonsurgical endodontic retreatment cases. *J Endod*. 1989; 15(6):261-6.

16. Hoen MM, Pink FE. Contemporary endodontic retreatments: an analysis based on clinical treatment findings. *J Endod.* 2002; 28(12):834-6.
17. Khan AM, Tirmazi SM, Adil S, Bangash NI, Munir B. Frequency of root canals in mandibular third molars of patients undergoing root canal treatment. *Pak Oral Dent J.* 2016; 36(2):323-6.
18. Cosić J, Galić N, Vodanović M, Njemirovskij V, Segović S, Pavelić B, et al. An in vitro morphological investigation of the endodontic spaces of third molars. *Coll Antropol.* 2013; 37(2):437-42.
19. Sert S, Şahinkesen G, Topçu FT, Eroğlu ŞE, Oktay EA. Root canal configurations of third molar teeth. A comparison with first and second molars in the Turkish population. *Aust Endod J.* 2011; 37(3):109-17.
20. Ahmad IA, Azzeh MM, Zwiri AM, Haija MASA, Diab MM. Root and root canal morphology of third molars in a Jordanian subpopulation. *Saudi Endod J.* 2016; 6(3):113-21.
21. Zafar S, Tabassum S, Sabharwal S, Rai VK, Srinivasan A, Tanniru HI. A stereomicroscopic in-vitro study to investigate the root canal morphology of mandibular third molars using clearing technique. *J Res Dent.* 2015;3(1):567-75.
22. Mukhaimer RH. Evaluation of root canal configuration of mandibular first molars in a palestinian population by using cone-beam computed tomography: an ex vivo study. *Int Sch Res Notices.* 2014; 2014:583621. doi: 10.1155/2014/583621
23. Kuzekanani M, Haghani J, Nosrati H. Root and canal morphology of mandibular third molars in an Iranian population. *J Dent Res Dent Clin Dent Prospects.* 2012;6(3):85-8. doi: 10.5681/joddd.2012.018



AUTHOR AFFILIATION:

Dr. Muhammad Rauf Ahmed

Assistant Professor of Operative Dentistry

Faisalabad Medical University Faisalabad, Punjab-Pakistan.

Email: drmohammadrauf@gmail.com