

Well Differentiated Neuro-Endocrine Tumor of the Stomach: A Case Report

Anwar Ali Jamali, Ghulam Mustafa Jamali, Syed Ghulam Mujtaba Shah

ABSTRACT

A 25 year old Sindhi speaking Pakistani male presented to his physician with history of dysphagia and weight loss. After initial evaluation and routine investigations patient was referred to gastroenterology unit for endoscopic evaluation and diagnosis.

KEY WORDS: Neuro-endocrine Tumor, Stomach, Well Differentiated.

This article may be cited as: Jamali AA, Jamali GM, Shah SGM. Well Differentiated Neuro-Endocrine Tumor of the Stomach: A Case Report. J Liaquat Uni Med Health Sci. 2018;17(03):190-4. doi: 10.22442/jlumhs.181730576

INTRODUCTION

Neuroendocrine tumors are regarded as functional when tumor cells produce hormones in excessive amounts and produce a specific clinical syndrome, about 2/3 of the neuroendocrine tumors are functional¹. The annual incidence of neuroendocrine tumors both in children and adults is approximated to be 2 to 5 cases per 100,000 populace^{2,3,4}. Neuroendocrine tumors are classified functional or non-functional; they may be benign or malignant. Pancreatic Neuroendocrine tumors are usually malignant (up to 90%). The locoregional insulinomas are the primary benign tumors³. Carcinoid syndrome that results due to carcinoid tumors is example of functional neuroendocrine tumors. Insulinomas, gastrinomas, VIPomas (vasoactive intestinal peptide), glucagonomas and somatostatinomas are examples of Pancreatic Neuroendocrine tumors⁵.

Definitions of Neuroendocrine tumors differ by the primary site of the tumor; on the other hand staging depends mainly upon the tumor size and level of invasion into the anatomical structures.

Grading for carcinoid and PNeuroendocrine tumors is dependent on the proliferation rate that is the number of mitosis per 10 microscopic high power fields or per 2 mm² or by Ki- 67 index (percentage of tumor cells that positively immunolabel for Ki-67 antigen). There is no clinical syndrome related to nonfunctional neuroendocrine tumors, symptoms such as abdominal pain and bloating can be produced in relation to the tumor or its metastases^{6,7}. Usually, nonfunctional P neuroendocrine tumors are twice as frequent as insulinomas, that are more common than gastrinomas > glucagonomas > VIPomas > somatostatinomas⁸. Well-differentiated neuroendocrine tumors are

generally of low to intermediate grade while less differentiated neuroendocrine tumors are frequently of high grade⁹. In present case a less common tumor of stomach was diagnosed. Our aim of this case presentation was to present and discuss management of this rare case.

CASE REPORT

This case study was conducted at the Department of Medicine, Peoples University of Medical and Health Sciences Hospital Nawabshah. Only one case was investigated during the period from 1st January 2018 to 15th February 2018.

History

22 years young educated male, resident of Nawabshah district Shaheed Benazirabad Sindh Pakistan with positive family history of cancers. After learning through internet he became over conscious about the possibility that he may develop cancer in gut. He consulted a physician and discussed his case and he was advised for certain routine and special investigations. On general survey a young healthy male not looking ill, of average height, conscious and cooperative. There was a positive family history of gastrointestinal malignancy, his younger brother died 04 month back due to stomach cancer, and father died 2 years back because of esophageal cancer no authentic record of father and brother was available. As there was no other clinically significant history of disease in past, addiction, transfusion, allergy, drugs, alcoholism and other illness. On examination a young healthy male not looking ill pulse 90b/min/low vol. BP 110/70mmHg, temp 98.6F and respiratory rate 16 breaths / minute. His BMI was normal. General physical examination was unremarkable. Cardiovas-

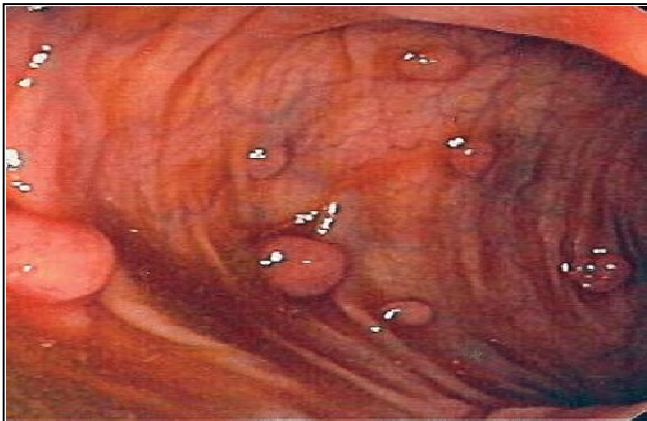cular, respiratory, neurological, abdomen, clinical signs and symptoms of endocrine system were checked and examinations were done and all were within normal limits.

INVESTIGATIONS

Chest x-ray, ECG and ultra sound abdomen were within normal limits.

Blood CBC (Complete blood count) revealed; RBCs 4.54 mil/cumm, (HB level 12.8 g%, ESR 10 mm/hr, HCT 39.2%, MCV 82.2fl, MCH 29.6pg, MCHC 36.6g/dl). WBC 6500/cumm, (N=58, L=40, E=01, M=01, B=00). Platelets count was 250000/cumm. Liver chemistry was within normal limits (Billurubin Total=1.0 mg%, Billurubin direct=0.66mg%, Billurubin indirect=0.44mg%, SGPT=35.0 u/l, Alkaline Phosphatase=188.4u/l, g-GT=12.4u/l). Antibodies against H. pylori antigen were negative. Random Blood Sugar was 144.6mg/dl, serum Creatinine value was 1.0mg/dl, and blood urea level was 40/dl, sodium 135 meq/dl, potassium 4.0 meq/l, Chloride 112 mmol/l and HCo₃ 24mmol/l. Prothrombin Time 12 Seconds, (Control=12seconds). Activated Prothrombin Time was 32 seconds, (control=32 seconds). Routine Viral markers were advised and checked all including HCV, HBV, and HIV were negative. MP ICT antigen was negative as a routine part of checkup. Urine D/R report Normal. Stool examination normal, negative for stool occult blood. Serum Gastrin level was 465pg/ml (normal 0-89pg/ml).

FIGURE I: UPPER GI ENDOSCOPY SHOWING MULTIPLE SESSILE POLYPS

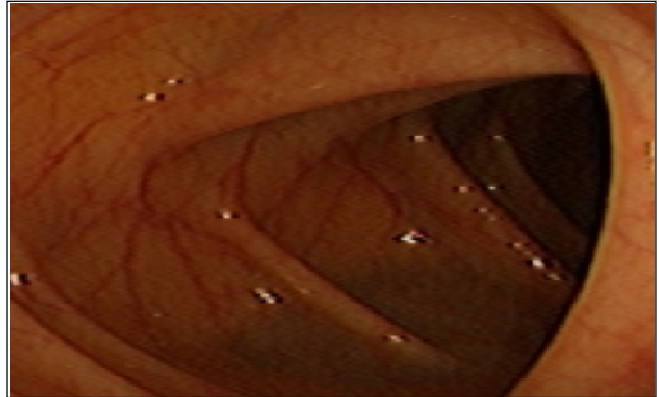


Upper GI endoscopy

Esophagus: tight stricture at upper esophageal sphincter which was dilated no biopsy was taken.

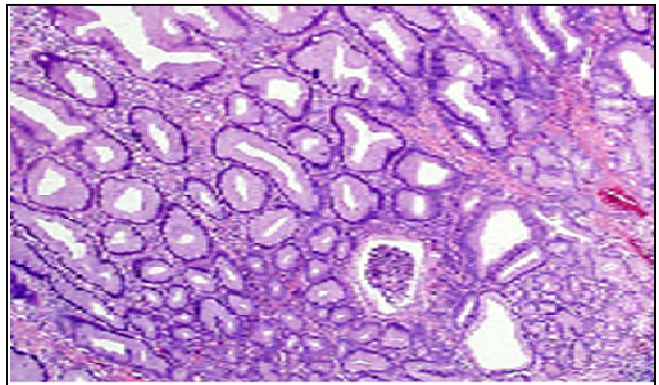
Stomach: mucosa of fundus, body antrum and pylorus appeared mildly erythematous and edematous. Multiple sessile polyps about 08 in number were seen in stomach. Duodenum appeared normal (Figure I).

FIGURE II: COLONOSCOPY WITH NORMAL COLON



Lower GI Endoscopy. Colonoscopy done was normal (Figure II)

FIGURE III: HISTOPATHOLOGY OF SESSILE POLYPS



Biopsy Report

Gross description: The specimen is received in formalin coded as "stomach polyp" it consist of 4 grey white tissue fragments measuring .4x.4cm in aggregates. Tissue Fragments having surface epithelium of columner cells and also exhibit goblet cell metaplasia. Lamina propria has moderate lymphoplasmacytic infiltrates Specimen was entirely submitted into single cassette (Figure III).

Microscopic examination: Section examined revealed nodular tissue fragments of gastric mucosa with most of the fragments having surface epithelium of columner cells and also exhibit goblet cell metaplasia. Lamina propria has moderate lymphoplasmacytic infiltrates and there are nests of relatively monotonous cells, which show pale cytoplasm and neucleie are mildly hyperchromatic. Focal cribriform pattern is also seen. These nests are present in lamina propria and between the smooth muscle fibers of the muscularis mucosae. The rest of areas in the gastric fragments don't show dysplasia. Immuno-histo-chemical stains were performed which

show the following activity pattern:

Synaptophysin positive

CD56 positive

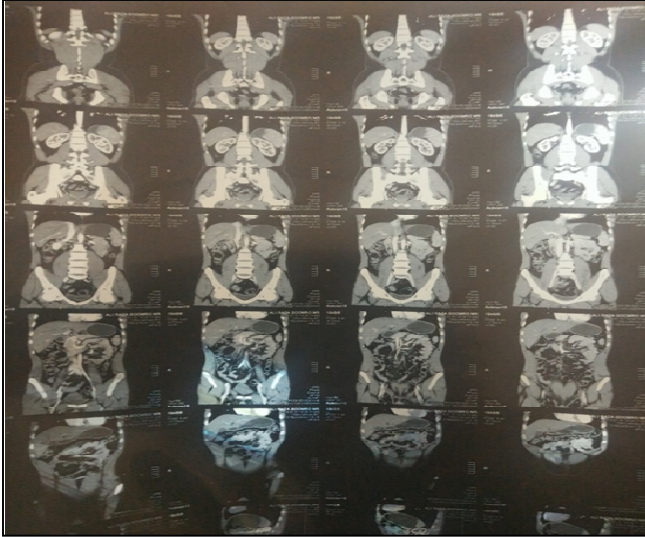Cytokeratin & positive

Ki-67 levels < 2%.

Cytokeratin 20 negative

Diagnosis: Stomach polyp; well differentiated neuroendocrine neoplasm grade I.

FIGURE IV: CT SCAN ABDOMEN



CT Scan Abdomen

Stomach appears distended with water density fluid showing normal wall thickness; no evidence of discrete mass is seen. Liver, spleen, kidneys, pancreas, urinary bladder, lymphnodes, small and large bowel normal no evidence of specific lesion is seen.

The limit of CT scan abdomen to detect the lesion was if the lesion is more than 2cms (**Figure IV**).

DISCUSSION

This is the first Case study about “Neuro-endocrine Tumor of the Stomach” was conducted during month of 1st January 2018 to 15th February 2018 at the Department of Medicine, Peoples University of Medical and Health Sciences Hospital Nawabshah, Sindh-Pakistan.

NEN (Neuroendocrine neoplasm) is an uncommon tumor of epithelial origin occurring at multiple sites with well neuroendocrine differentiation⁷. They are usually split by origin of location. Fore gut (34%) tumors originate from lungs, bronchus, stomach or duodenum, mid gut tumors (30%) arise from jejunum, ileum, appendix or colon (proximal) and hind gut tumors (36%) arise from distal colon or rectum¹⁰.

Neuroendocrine neoplasms of gastric origin are classified as NET (neuroendocrine tumors), NEC (neuroendocrine carcinoma), adenoneuroendocrine

carcinoma (mixed), enterochromaffin cells, serotonin and gastrin producing neuroendocrine tumors. Neuroendocrine tumors consists carcinoid (NET G1) and well differentiated neuroendocrine tumor/carcinoma (NET G2). Neuroendocrine carcinomas consists poorly differentiated neuroendocrine carcinoma small cell/large cell type (NEC G3)¹¹. Tumors which arise from neuroendocrine cells are present all through body. Lubarsch was the first to describe these tumors about a century ago; he found multiple tumors at distal ileum on autopsy of two patients¹². Historically, these tumors originate from foregut, midgut, or hindgut. In the majority of patients midgut is the most common site of primary location². WHO criterion (2010) for classification of NENs in NETs or NECs is based according to cellular proliferation as NET G1 low grade, NET G2 intermediate grade and NET G3 as high grade neuro-endocrine tumor with mitotic and Ki-67 indices. In present case Immuno-histo-chemical stains were performed which showed: Synaptophysin positive, CD56 positive, Cytokeratin & positive, Cytokeratin 20 negative and Ki-67 index < 2% and diagnosed as well differentiated neuro endocrine tumor grade 1 (NET G1). This was highly matchable with our case finding whose Diagnosis was Stomach polyp; well differentiated neuroendocrine neoplasm grade 1. Usually these tumors can be removed through endoscopic procedures followed by resections, but the cancers of neuroendocrine nature always need radical surgery for resections¹³. Gastric NEN has different prognoses and treatments depending on type. Prognosis and treatment is variable and depends upon the type of neoplasm, in NET G1 prognosis is good with survival rate of five years, NET G2 is aggressive and have favorable prognosis. The NEC has poor prognosis and is highly malignant but had survival rate of five years in 75-80% of patients. Treatment options range from endoscopic resection in NET to surgical resection and lymph node dissection in NEC¹⁴. Cisplatin-based chemotherapy is the most excellent option for adjuvant chemotherapy in NEC patients¹⁵.

The overall incidence of GNET had increased due to more valid diagnostic facilities and interventions like upper GI endoscopy¹⁶. This statement is favored in our case report here the awareness of subject lead to diagnosis. Since long use of acid suppressant reported the association between PPI and Gastric NET¹⁷. The past history of acid suppressants was not present in our case, likely excluding the one cause related to PPI use.

Deficiency of proper management guidelines is important issue. Stomach NET were not assessed individually, there is a great need of prospective

research on wide scale¹⁸.

Tumors of stomach under heading of GNET are very rare; ratio is increasing day by day. Various factors had been identified to assess the prognosis of these cases like duration, sex, age group, size, site, grading and staging and other factors. These variables affect the outcome of disease in terms of morbidity and mortality¹⁹.

There were no current or past researches available in the form of randomized control or retrospective studies available on GNET in Pakistan.

As reported and searched from internet sources very little data regarding the gastric neuroendocrine tumors are available from Pakistan, but few cases have been reported from India, where they reported a benign nature neuroendocrine tumor²⁰.

After confirmation of diagnosis the patient was advised for the follow up endoscopies, and offered removal of polyps by endoscopic procedure polypectomy and surgical option in future.

The patient selected the option of surveillance endoscopies and regular follow-ups.

CONCLUSION

Gastric NETs are rare in young population, and at present no specific guidelines for diagnosis and treatment are available. North American Neuroendocrine Tumor Society (NANETS) adult-based guidelines are supportive in managing this ailment. In the extended run, gathering of clinically helpful treatment information and long standing follow up guidelines must facilitate the practitioners to improve customary care specified to young patients having NETs.

Our case was diagnosed in early phase proper follow up and timely intervention may reduce the morbidity and mortality in this case.

RECOMMENDATIONS

All the patients who have strong family history of gastrointestinal malignancies should routinely undergo diagnostic upper and lower GI endoscopies along with routine consultations.

It is recommended that periodic evaluation clinical, laboratory as well as intervention are necessary in those cases when there is strong positive history of malignancy in the family at early ages. To establish and to assess effectiveness of treatment randomized multicenter control trials of disease are needed. These should be followed with valid national or international guidelines as recommended.

REFERENCES

1. Oberg K, Castellano D. Current knowledge on diagnosis and staging of neuroendocrine tumors. *Cancer Metastasis Rev* 2011; 30(1): 3-7. doi: 10.1007/s10555-011-9292-1.
2. Verbeek WH, Korse CM, Tesselaar ME. GEP-NETs UPDATE: Secreting gastroenteropancreatic neuroendocrine tumours and biomarkers. *Eur J Endocrinol* 2016; 174(1): R1-7. doi: 10.1530/EJE-14-0971.
3. Ilett EE, Langer SW, Olsen IH, Federspiel B, Kjær A, Knigge U. Neuroendocrine carcinomas of the Gastroenteropancreatic system: A comprehensive review. *Diagnostics (Basel)* 2015; 5(2): 119-176. doi: 10.3390/diagnostics5020119
4. Schultz C, Schütte K, Malfertheiner P. Rare Neoplasia of the Stomach. *Gastrointest Tumors* 2015; 2(2): 52-60. doi: 10.1159/000435899.
5. Yao JC, Hassan M, Phan A, Dagohoy C, Leary C, Mares JE, et al. One hundred years after "carcinoid": epidemiology of and prognostic factors for neuroendocrine tumors in 35,825 cases in the United States. *J Clin Oncol* 2008; 26(18): 3063-72. doi: 10.1200/JCO.2007.15.4377.
6. Kulke MH, Anthony LB, Bushnell DL, de Herder WW, Goldsmith SJ, Klimstra DS, et al. NANETS treatment guidelines: well-differentiated neuroendocrine tumors of the stomach and pancreas. *Pancreas* 2010;39(6): 735-52. doi: 10.1097/MPA.0b013e3181ebb168.
7. Modlin IM, Oberg K, Chung DC, Jensen RT, de Herder WW, Thakker RV, et al. Gastroenteropancreatic neuroendocrine tumours. *Lancet Oncol* 2008; 9(1): 61-72. doi: 10.1016/S1470-2045(07)70410-2.
8. Vinik AI, Woltering EA, Warner RR, Caplin M, O'Dorisio TM, Wiseman GA, et al. NANETS consensus guidelines for the diagnosis of neuroendocrine tumor. *Pancreas* 2010; 39(6): 713-34. doi: 10.1097/MPA.0b013e3181ebaffd.
9. Klimstra DS, Modlin IR, Coppola D, Lloyd RV, Suster S. The pathologic classification of neuroendocrine tumors: a review of nomenclature, grading, and staging systems. *Pancreas* 2010; 39(6): 707-12. doi: 10.1097/MPA.0b013e3181ec124e.
10. Klöppel G, Anlauf M. Epidemiology, tumour biology and histopathological classification of neuroendocrine tumours of the gastrointestinal tract. *Best Pract Res Clin Gastroenterol* 2005; 19(4): 507-17.
11. Bosman FT, Carneiro F, Hruban RH, Theise ND. 4th ed. WHO Press; Geneva, Switzerland: 2010. World Health, Organization (WHO) Classification of Tumours of the Digestive System.
12. Valentino J, Evers BM. Recent Advances in the Diagnosis and Treatment of Gastrointestinal Carcinoids. *Adv Surg* 2011; 45(1): 285-300. DOI:

- <https://doi.org/10.1016/j.yasu.2011.03.014>
13. Kang S H, Kim K H, Seo SH, An MS, Ha TK, Park HK, et al. Neuroendocrine carcinoma of the stomach. A case report. *World J Gastrointest Surg* 2014; 6(4): 77–79. doi: 10.4240/wjgs.v6.i4.77
 14. Kim BS, Oh ST, Yook JH, Kim KC, Kim MG, Jeong JW, et al. Typical carcinoids and neuroendocrine carcinomas of the stomach: differing clinical courses and prognoses. *Am J Surg* 2010; 200(3): 328-33. Doi: 10.1016/j.amjsurg.2009.10.028.
 15. Okita NT, Kato K, Takahari D, Hirashima Y, Nakajima TE, Matsubara J, et al. Neuroendocrine tumors of the stomach: chemotherapy with cisplatin plus irinotecan is effective for gastric poorly-differentiated neuroendocrine carcinoma. *Gastric Cancer*. 2011; 14(2): 161-65. doi: 10.1007/s10120-011-0025-5.
 16. Chen WF, Zhou PH, Li QL, Xu MD, Yao LQ. Clinical impact of endoscopic submucosal dissection for gastric neuroendocrine tumors: a retrospective study from mainland China. *Scientific World J* 2012; 2012: 869769. doi: 10.1100/2012/869769
 17. Jianu CS, Lange OJ, Viset T, Qvigstad G, Martinsen TC, Fougner R, et al. Gastric neuroendocrine carcinoma after long-term use of proton pump inhibitor. *Scand J Gastroenterol* 2012; 47(1):64–67. doi: 10.3109/00365521.2011.627444.
 18. Kim SY, Woo IS, Yang JH, Han CW, Roh SY, Jung YH. A Case of Metastatic Gastric Neuroendocrine Tumor: Therapeutic Considerations. *Case Rep Oncol* 2014; 7:266-272. doi: 10.1159/000362516
 19. Yang Z, Wang W, Lu J, Pan G, Pan Z, Chen Q, et al. Gastric Neuroendocrine Tumors (G-Nets): Incidence, Prognosis and Recent Trend Toward Improved Survival. *Cell Physiol Biochem* 2018; 45(1):389–96. Doi:10.1159/000486915
 20. Samaras VD, Foukas PG, Triantafyllou K, Leonardara V, Tsapralis D, Tsompanidi E, et al. Synchronous well differentiated neuroendocrine tumour and gastrointestinal stromal tumour of the stomach: a case report. *BMC Gastroenterol* 2011; 11:27. doi:10.1186/1471-230X-11-27



AUTHOR AFFILIATION:

Dr. Anwar Ali Jamali (*Corresponding Author*)

Assistant Professor, Department of Medicine
Peoples University of Medical and Health Sciences
Nawabshah, Sindh-Pakistan.
Email: jamalianwarali@gmail.com

Dr. Ghulam Mustafa Jamali

Senior Registrar, Department of Medicine
Peoples University of Medical and Health Sciences
Nawabshah, Sindh-Pakistan.

Dr. Syed Ghulam Mujtaba Shah

Department of Physiology
Peoples University of Medical and Health Sciences
Nawabshah, Sindh-Pakistan.