

# Innovative method of Intervention: Modified-Internal Joint Stabilizer-Elbow for Acute and Chronic Elbow Dislocation

Shuja Uddin<sup>1\*</sup>, Syed Rizwan ul Haq<sup>1</sup>, Hafiz M. Umar<sup>1</sup>, Husnain Khalid<sup>1</sup>,  
Muhammad Khalid Syed<sup>1</sup>, Muhammad Mian Haneef<sup>1</sup>

## ABSTRACT

**OBJECTIVE:** To evaluate utilization, range of mobility at the end of the follow-up, DASH scores, and the necessity for additional operations.

**METHODOLOGY:** Twelve patients with acute or chronic elbow dislocation from Jan 2022 to March 2023 were selected for study after written consent. Sampling was done with a non-probability sampling technique. Infection and age less than 20 & more than 70 years were exclusion criteria.

**RESULTS:** Average extension-flexion arcs at the final follow-up were 21.84-108.57 degrees, while pronation-supination motion under normal level was 10.2-120 degrees. 91.66 percent of patients achieved > 100-degree arcs of both flexion-extension. The average DASH score was 17.99.

**CONCLUSION:** Modified IJS is an affordable method of elbow stabilization with an early range of motion, and concentric reduction is modified IJS. It is simple to use and delivers good functional results.

**KEYWORDS:** Elbow dislocation, terrible triad, Modified-Internal Joint, Elbow, Chronic.

## INTRODUCTION

Managing an unstable elbow following an injury or surgical release is often tricky<sup>1</sup>. Elbow dislocation is a common injury treated by Orthopaedic surgeons, with a documented frequency of 5.21 for every 100,000 person-years<sup>2</sup>. Dislocations in the posterior and posterolateral limbs constitute approximately 80% of all dislocations that occur<sup>3</sup>. The elbows with extensive fracture dislocations, such as dreadful triad lesions and problematic coronoid fractures, may remain unstable following fracture treatment<sup>4</sup>. Acute elbow dislocations with significant delicate tissue damage, as well as those in grossly obese patients, may be problematic after reduction. Elbows that have undergone procedures for reconstruction that require considerable release of periarticular delicate layers of tissue and/or excision of heterotopic bone frequently become unstable, impeding or postponing rehabilitation<sup>5</sup>. Chronicity of elbow dislocation, described as an unreduced joint for more than two weeks<sup>4</sup>, is uncommon in the United States; hence, most literature comes from third-world nations<sup>6</sup>. If not appropriately treated, prolonged elbow dislocation causes fast arthritis, extreme instability, significant discomfort, and reduced elbow functionality<sup>7</sup>. To preserve joint stability and unity, many patients require surgical treatments such as prolonged immobilization in the position of flexion, prostheses or devices, or

external and/or articular stabilization<sup>8,9</sup>.

As a result, in the many series published in the literature, these types of injuries are linked with substantial morbidity and revision surgery<sup>10-12</sup>.

Surgeons are looking for ways to improve the management of this type of recurrent elbow injury, both conceptually and technically, regardless of proper restitution of the collateral ligament complex, coronoid process, and head of radius.

The contradictory goals of recovering elbow stability while preserving a reasonable arc of motion make therapies for chronic elbow dislocation difficult. Because soft tissue contracture around the joint usually occurs beyond two weeks, making appropriate closed reduction practically impossible, chronic elbow dislocation therapy necessitates open reduction.<sup>15,16</sup> Following that, a hinged external fixator or cast is frequently attached to maintain stability and permit movement.

To achieve these developments, Orbay JL2014<sup>13</sup> announced initial findings employing an inner elbow stabilizing method established on the installation of a Steinmann pin via longitudinal alignment of the ulnohumeral and affixed to proximal ulna, through encouraging findings for the support of utilizing such a kind of dynamic internal fixation methodology as a successor to the external device.

The advantage of this operation is the restoration of stability and the capacity to preserve a proper arc of motion because they lack the thickness and weight of external fixators; IJS implants are also straightforward to maintain for patients. We modified the implant with less cost and one-piece construct via T-plate as

<sup>1</sup>Department of Orthopedics, Lahore General Hospital, Lahore, Pakistan

Correspondence: drshujauddin111@gmail.com  
doi: 10.22442/jlumhs.2023.00000



Mod-IJS-E for third-world countries.

## METHODOLOGY

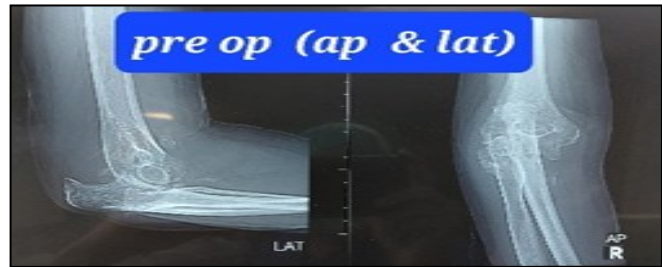
Indications of utilization, various degrees of motion during the final check/follow-up, DASH scores, and following the implementation of modified IJS-E, the requirement for future procedures, were examined during the study.

From January 2022 to March 2023, we included 12 patients at Lahore General Hospital in Lahore who met the inclusion criteria of acute and chronic traumatic elbow instability, recurrent TTEI after surgical repair, and the need to neutralize the tenuous fixation of an unstable coronoid fracture. The minimal period of follow-up was six months. There were no patients who went missing to follow-up.

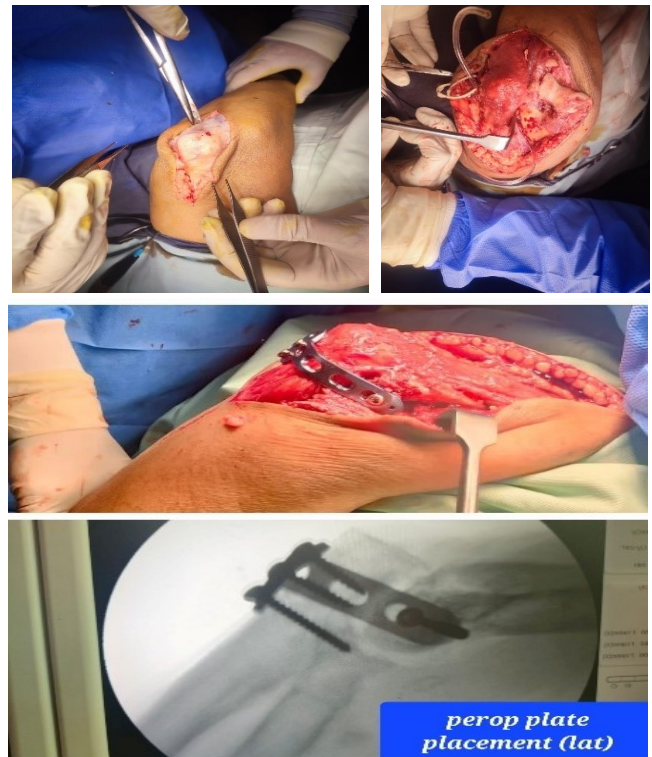
**Surgical technique:** Preoperative radiographs commonly show posterior dislocation and considerable osteoporosis in cases of chronic elbow dislocation. The patients were placed in lateral decubitus in the operating room with the arm bolster. A posterior approach to the elbow was adopted, and an algorithm was followed. In the case of fractures, reduce the dislocation and fix the coronoid and radial head first. Then, the collaterals were assessed, and repair was performed for the affected collaterals. Then, a modified Internal joint stabilizer was applied to neutralize and stabilize the joint in its congruences. Modified techniques were applied by bending the 4-hole T-plate (nonlocking) 90 degrees.

Firstly, after achieving the joint unity and removal of heterotrophic ossificans (if present), the last hole on the vertical limb of the T-plate was purchased over the capitellum with a 4mm cancellous screw in a transverse pattern from the lateral to medial aspect but not penetrating the medial cortex. The transverse limb of the plate was fixed over the olecranon; two cortical 3.5mm screws in the olecranon and one 3.5mm screw in the coronoid. All screws were confirmed under the image intensifier. The ulnar nerve was secured and anteriorly transposed in cases of chronicity. An additional procedure, capsulotomies, was also performed if joint ROM was reduced. The joint arc of motion was confirmed peri-operatively and under an image intensifier. All patients were explained in detail regarding the passive range of motion for the first week and active ROM from the second postoperative week. All patients were checked in the second and fourth weeks. Then, once monthly onward for a further five months. On each patient's subsequent follow-up visits, we examine elbow movement, comprising flexion/extension & pronation/supination of the elbow, finger movements, radiological symmetry, and DASH score. After the first eight weeks, when soft tissue repair is predicted to maintain stability, we planned to remove IJS through subsequent surgery.

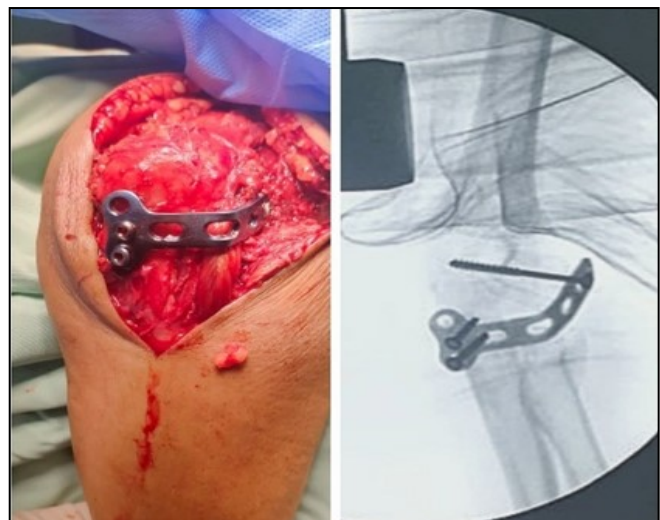
**Figure I: Pre-op x-ray of chronic dislocation**



**Figure II: Per-op Picture of a plate with a lateral view**



**Figure III: Per-op picture of a plate with a posterior view**



## RESULTS

The average extension-flexion arcs were 21.84-108.57 degrees (**Table I**), while the pronation-supination motion was 8.2-120 degrees. 91.66 percent of patients attained flexion-extension arcs of greater than 100 degrees. The DASH average was 17.99 (**Table II**). Additional surgeries were necessary for six patients: LUCL reconstruction in four patients, coronoid fixation in three patients, and radial head fixation in three. The list of complications includes screw loosening, one olecranon screw & 1 capitellar screw (16.6%), and 16.6 % infection; 2 pin tract of axis screw.

**Table I: DASH score on every follow-up of each patient**

Cases	2 <sup>nd</sup> week	4 <sup>th</sup> week	8 <sup>th</sup> week	12 <sup>th</sup> week	16 <sup>th</sup> week	20 <sup>th</sup> week	24 <sup>th</sup> week	Mean DASH score
No. 1	28.8	26.4	22.4	18.3	14.5	13	6.6	18.57
No. 2	30.1	28.3	24.6	19.6	18.3	14.6	8.3	20.54
No. 3	23.1	22.8	19.2	16.8	11.6	10.3	11.5	16.47
No. 4	28.6	20.6	18.4	14.3	12.4	11.1	9.7	16.44
No. 5	30.7	24.2	22.7	12.6	12.2	10.7	7.4	17.21
No. 6	29.5	26.6	20.2	12.2	12.6	10.3	9.3	17.24
No. 7	29.2	26.3	22.5	14.1	12.5	11.2	7.5	17.61
No. 8	28.6	25.5	24.6	15.6	14.5	10.5	9.7	18.42
No. 9	28.4	22.3	20.3	14.4	13.3	10.7	8.5	16.84
No. 10	27.7	25.7	25.6	15.7	14.7	12.2	10.6	18.88
No. 11	28.7	28.2	24.3	13.4	12.1	11.3	11.3	18.47
No. 12	32.4	28.4	24.7	14.8	12.6	11.5	9.8	19.17
<b>Average DASH score</b>								<b>17.99</b>

**Table II: Extension-Flexion arc range (in degree) after completion of follow-ups**

	Mean extension-flexion range of each pt
No. 1	22.85-111.42
No. 2	20.71-107.14
No. 3	24.28-112.14
No. 4	17.85-112.14
No. 5	20-115.71
No. 6	22.14-112.14
No. 7	15.71-77.142
No. 8	27.14-115.71
No. 9	26.42-111.42
No. 10	25.71-112.14
No. 11	17.85-107.14
No. 12	21.42-111.42
<b>Average Ext-flexion range</b>	<b>21.84-108.57</b>

## DISCUSSION

Chronic elbow dislocations remain a substantial issue for surgeons, with devastating consequences. They are frequently linked to severe instability, reduced elbow function, continuing pain, and arthritic changes<sup>17,18</sup>. We included both chronic and acute elbow dislocation cases. We achieved a decent average arc of elbow extension-flexion arc, 21.84-108.57 and pronation supination. Salazar LM 2022<sup>20</sup> demonstrated that an internally placed stabilizer of the joint may effectively augment conventional therapy methods and restore elbow stability in people with obesity, concurrent medical conditions, and complicated fractured morphologies.

McKee MD 2005<sup>18</sup> and McKee MD et al.<sup>4</sup> showed comparable outcomes, with an average arc of motion of 112° and 105°. Munoz MA et al.<sup>9</sup> present favorable findings in their dataset released in 2019 with an overall number of 62 TTIE addressed appropriately, with an average flexion-extension arc of 100° and mean values on the MEP scale of 92 points. It was noted that up to 22% of the cases in their series required static external fixation, and 27% of those instances experienced complications, the most common of which was nerve injury. Our study identified 16.6% of patients with infection, two with superficial hematoma and two with implant loosening. A comparison of external fixation and trans articular fixation was made by Ring D 2014<sup>12</sup> for primary repair adjuvancy, explaining a more significant proportion of challenges associated with external fixation (50% vs 10%) despite beneficial functional outcomes across both groups 90 points on the Broberg and Morrey scale and an average flexion-extension range of motion of 100°. Similar outcomes in motion employing external fixation may be seen in the literature for the

series 109°, 12, 120°, 18 and 105°<sup>11</sup>. Our study, however, demonstrates a minimal risk of complications and a satisfactory ROM arc.

Orbay JL 2014<sup>13</sup> used the IJS-E device instead of external fixation, which they developed separately in 24 patients. The final standard range of movement was 119° for flexion extension and 152° for pronation/supination. These findings matched our previous study, which used a different implant. In our research, we attained values between 21.84 and 108.57 and the complete range of pronation/supination comparable to those indicated above. These findings were echoed by Sochol KM 2019<sup>11</sup> in their use of the IJS to demonstrate beneficial DASH scores. The study also implies that, unlike external fixators, IJS devices do not need to be removed unless patients request it, even if secondary removal of an IJS is recommended at 6-8 weeks.

In our study, after 8 to 10 weeks, all patients required the removal plate. Notably, no research has been done on how the IJS might be implanted permanently. Since their inception, IJS device indications have been diverse and arbitrary. We followed the advice of the most current study on IJS use by Pasternack JB 2020<sup>19</sup> and included five chronic cases. The IJS was indicated for both acute and chronic elbow instability.

## CONCLUSION

The modified IJS-E maintains concentric reduction, allows good elbow ROM, and avoids the complications faced during the external devices. This method is cost-effective and affordable for each patient.

Ethical permission: Lahore General Hospital, Lahore ERC letter No. Nil

**Conflict of interest:** There is no conflict of interest

**Funding:** No funding disclosure

**Data Sharing Statement:** The corresponding author can provide the data proving the findings of this study on request. Privacy or ethical restrictions bound us from sharing the data publically.

## AUTHOR CONTRIBUTION

Uddin S: Data collection  
 ul Haq SR: Data collection  
 Umar HM : Statistics  
 Khalid H: Proof reading  
 Syed MK: Proof reading, plagiarism  
 Haneef MM: Manuscript writing

## REFERENCES

- Egol KA, Immerman I, Paksima N, Tejwani N, Koval KJ. Fracture-dislocation of the elbow functional outcome following treatment with a standardized protocol. *Bull NYU Hosp Jt Dis.* 2007; 65: 263-270.
- Stoneback JW, Owens BD, Sykes J, Athwal GS, Pointer L, Wolf JM. Incidence of elbow dislocations in the United States population. *J Bone Joint Surg Am.* 2012; 94: 240-5. doi: 10.2106-JBJS.J.01663.
- Donohue KW, Mehlhoff TL. Chronic elbow dislocation: evaluation and management. *J Am Acad Orthop Surg.* 2016; 24(7): 413-23. doi: 10.5435/JAAOS-D-14-00460.
- McKee MD, Bowden SH, King GJ, Patterson SD, Jupiter JB, Bamberger B et al. Management of recurrent, complex instability of the elbow with a hinged external fixator. *J Bone Joint Surg Br.* 1998; 80(6): 1031-6. doi: 10.1302-0301-620X.80B6.8536.
- O'Driscoll SW, Jupiter JB, King GJW, Hotchkiss RN, Morrey BF. The unstable elbow. *Instr Course Lect.* 2001; 50: 89-102.
- Morrey BF. Chronic Unreduced Elbow Dislocation. In: Morrey BF, SanchezSotelo J, Morrey ME, editors. *Morrey's The Elbow and Its Disorders.* Philadelphia: Elsevier; 2018. p. 521-8 (ISBN No. 9780323341691).
- Jupiter JB, Ring D. Treatment of unreduced elbow dislocations with hinged external fixation. *J Bone Joint Surg Am* 2002; 84(9): 1630-5. doi: 10.2106/00004623-200209000-00017.
- Lindhovius ALC, Jupiter JB, Ring D. Comparison of acute versus subacute treatment of terrible triad injuries of the elbow. *J Hand Surg Am.* 2008; 33(6): 920-6. doi: 10.1016/j.jhsa.2008.02.007.
- Muñoz MA, Pardo García JM, Lamas LG, Moreno MP, Díaz VJ, López DC. Protocolised surgical treatment of terrible triad of elbow. Results and complications. *Rev Esp Cir Ortop Traumatol(Engl Ed).* 2019; 63(4): 281-8. doi: 10.1016/j.recot.2019.02.003. Epub 2019 May 22.
- Chen H, Liu GD, Wu LJ. Complications of treating terrible triad injury of the elbow: A systematic review. *PLoS One.* 2014; 9(5): e97476. doi: 10.1371/journal.pone.0097476.
- Sochol KM, Andelman SM, Koehler SM, Hausman MR. Treatment of traumatic elbow instability with an internal joint stabilizer. *J Hand Surg Am* 2019; 44(2): 161.e1-161.e7. doi: 10.1016/j.jhsa.2018.05.031.
- Ring D, Bruinsma WE, Jupiter JB. Complications of hinged external fixation compared with cross-pinning of the elbow for acute and subacute instability. *Clin Orthop Relat Res.* 2014; 472(7): 2044-8. doi: 10.1007/s11999-014-3510-4.
- Orbay JL, Mijares MR. The management of elbow instability using an internal joint stabilizer: preliminary results. *Clin Orthop Relat Res.* 2014; 472(7): 2049-2060 doi:10.1007-s11999-014-

- 3646-2.
14. Orbay JL, Ring D, Kachooei AR, Santiago-Figueroa J, Bolano L, Pirela-Cruz M et al. Multicenter trial of an internal joint stabilizer for the elbow. *J Shoulder Elbow Surg.* 2017; 26(1): 125-132. doi: 10.1016/j.jse.2016.09.023.
  15. Allende G, Freytes M. Old dislocation of the elbow. *J Bone Joint Surg Am.* 1944; 26: 691-706.
  16. Lyons RP, Armstrong A. Chronically unreduced elbow dislocations. *Hand Clinics.* 2008; 24(1): 91-103. doi: 10.1016/j.hcl.2007.11.008.
  17. Jupiter JB, Ring D. Treatment of unreduced elbow dislocations with hinged external fixation. *J Bone Joint Surg Am.* 2002; 84(9): 1630-5. doi: 10.2106/00004623-200209000-00017.
  18. Mckee MD, Pugh DMW, Wild LM, Schemitsch EH, King GJW. Standard surgical protocol to treat elbow dislocations with radial head and coronoid fractures. Surgical technique. *J Bone Joint Surg Am.* 2005; 87(suppl 1(Pt 1)): 22-32. doi: 10.2106/JBJS.D.02933.
  19. Pasternack JB, Ciminero ML, Choueka J, Kang KK. Patient outcomes for the Internal Joint Stabilizer of the Elbow (IJS-E). *J Shoulder Elbow Surg.* 2020; 29(6): e238-e244. doi: 10.1016/j.jse.2019.12.018.
  20. Salazar LM, Koso RE, Dutta AK. Unique Indications for Internal Joint Stabilizer (IJS) for Elbow Instability. *J Shoulder Elbow Surg.* 2022; 31(11): 2308-2315. doi: 10.1016/j.jse.2022.04.002.

