

ORIGINAL ARTICLE

## Association of the c.75C>A Variant in CLCC1 with Autosomal Recessive Retinitis Pigmentosa in Pakistan

Yar Muhammad Waryah<sup>1\*</sup>, Feriha Fatima Khidri<sup>2</sup>, Amir Ansari<sup>3</sup>, Samia Mehmood<sup>4</sup>, Sumera Abbasi<sup>5</sup>, Shabahat Memon<sup>6</sup>

<sup>1</sup>Department of Molecular Biology & Genetics, Sindh Institute of Ophthalmology & Visual Sciences (SIOVS), Hyderabad, Sindh-Pakistan

<sup>2</sup>Department of Biochemistry, Bilawal Medical College, Jamshoro, Sindh-Pakistan

<sup>3</sup>Department of Medical Technology, Dow University Health Sciences, Karachi, Sindh-Pakistan

<sup>4</sup>Bilawal Medical College, Jamshoro, Sindh-Pakistan

<sup>5</sup>Department of Pathology, Liaquat University Hospital Hyderabad, Sindh-Pakistan

<sup>6</sup>Sindh Institute of Ophthalmology & Visual Sciences (SIOVS), Hyderabad, Sindh-Pakistan

**Correspondence:** yarmwaryah@hotmail.com

doi: 10.22442/jlumhs.2024.01151

### ABSTRACT

**OBJECTIVE:** To identify the disease-causing allele of retinitis pigmentosa, a heterogeneous genetic disorder in a single affected family.

**METHODOLOGY:** A cross-sectional descriptive study was conducted at the Sindh Institute of Ophthalmology & Visual Sciences Hyderabad from December 2022 to December 2023, with approval from the SIOVS ethical committee. A consanguineous pedigree with multiple affected members was included, while pedigrees with only one affected member or secondary causes of vision loss were excluded. After getting informed consent, each enrolled participant's blood samples (10 cc) were collected, and DNA was extracted. The family was subjected to Sanger sequencing for the CLCC1 gene.

**RESULTS:** In this study, one reported c.C75A, p.Asp25Glu allele in the CLCC1 gene was identified from endogamous pedigree located to Sindh, Pakistan. The identified c.C75A, p.Asp25Glu allele is a common to cause of autosomal recessive retinitis pigmentosa (arRP) in Pakistanis affected individuals. This allele is estimated to have occurred 2000-5000 years ago and has been transmitted to affected individuals of Pakistani origin and globally descent across various geographical regions. All the affected patients went for detailed clinical investigations, including fundus photography and optical coherence topography, were conducted for confirmation of the retinitis pigmentosa symptoms. The Sanger sequencing method was used to detect pathogenic variants, and bioinformatics tools were utilized to investigate the pathogenesis of identified alleles and compare phenotype-genotype correlations.

**CONCLUSION:** The finding of frequently disease causing alleles from Pakistani affected patients will significantly improve existing genetic databases and facilitate more accurately to the affected for diagnosis of genetic testing.

**KEYWORDS:** CLCC1 gene, night blindness, endogamous pedigree, genetic counseling, Sanger sequencing, phenotype-genotype correlation

**INTRODUCTION**

Retinitis pigmentosa (RP) is a rare set of clinically and genetically heterogeneous disorders; RP impairs the light-sensitive rod cells in the retina, causing progressive rod cell degeneration that results in low light and peripheral vision. Retinitis pigmentosa is expressed differently in isolated individuals(1); some lose eyesight more quickly, while others experience gradual vision loss. RP can also be linked to additional syndromic disorders such as developmental delays or hearing loss (2).

Retinitis Pigmentosa (RP) is a primary cause of hereditary blindness that varies frequently among different demographic groups. According to data from the United States and Europe, the prevalence of RP is approximately 1 in 4,000 people worldwide (3); the highest frequency was found in rural South India, where it was reported to be 1 in 372 (4). In Pakistan, the prevalence of RP is not reported, but according to a hospital-based study, 20% of students attending blind schools have this condition. Numerous factors, such as geographic location, ethnic background, and the specific genetic modifications at work, can affect these figures (5). Variable populations may have variable incidence rates for RP, a genetically heterogeneous disorder with diverse inheritance patterns and certain populations may have a higher frequency of specific genetic variations associated with RP, making them more susceptible to the disorder.

At least one hundred fifty 150 mutations were identified in nineteen genes with phenotypes manifesting RP associated symptoms (6). Non-syndromic RP can be inherited in three different ways: autosomal dominant in roughly 30–40% of instances, autosomal recessive in 50%–60% of cases (the most common hereditary RP globally), or X-linked in nearly 5%–15% of cases (7). There have also been isolated reports of the digenic or mitochondrial modes of inheritance. The most frequent forms of syndromic RP are Usher syndrome, which is the most common cause of collective blindness, deafness and Bardet-Biedl syndrome which RP characterizes along with polydactyly, obesity, renal abnormalities, hypogenitalism, and mental retardation.

Retinitis pigmentosa is the heterogeneous disorder and c.75C > A allele is a moderately common cause of arRP in the Pakistani population. Identifying c.75C > A allele associated with RP helps better understand the underlying genetic mechanisms driving the disease. Information provides insights into disease progression, potential treatment targets, and personalized medicine approaches.

**MATERIAL METHOD*****Ascertainment and clinical evaluation of families***

A cross-sectional descriptive study was carried out after approval from the ethical review committee of Sindh Institute of Ophthalmology & Visual Sciences during period of from December 2022 to December 2023. The consanguineous families manifesting the symptoms of night blindness and consisting of more than one affected were included, and the pedigree consists only one affected or secondary cause of blindness was excluded. This research identified over twenty affected families from different Eye Hospital in Sindh. Each affected patient underwent a clinical examination held by relevant supporting ophthalmology staff; the detailed history and clinical examination, including fundus examination and optical coherence topography were performed. After informed consent was obtained, ten cc of Venous blood sample was taken and placed in a 50 ml Falcon tube containing 200ul of 0.5M EDTA. DNA of all available participants in the pedigree was extracted through an optimized organic method (8), and 25ng dilution was prepared for PCR amplification.

***Mutation Screening and Bioinformatics Analysis***

Using the open-source Primer3 tool program, the sequencing primers for the CLCC1 gene were developed and optimized according to different annealing temperatures. The forward and reverse boundaries of the CLCC1 gene were amplified on all individuals available in pedigree using previously described techniques (9). Chromas v 2.5 was used to retrieve and evaluate Sanger sequencing results. Phyre2 was used to generate the 3D structures of the CLCC1 protein to distinguish it from the mutant protein, Ramachandran plots were created to determine the quality of the protein's three-dimensional structure by observing torsion angle values, and Clustal omega W was used to observe amino acid conservation alignment in different homologue species. These bioinformatics tools helped to determine the pathogenicity of the identified variants and to understand the potential impact on health.

**RESULTS**

The RP-01 family was registered from a remote location in Sindh, Pakistan and enrolled from tertiary care facility Layton Rahmatulla Benevolent Trust (LRBT) Rashid Abad. The clinical examinations identified the retinal degeneration condition in the family. Each affected individual displayed retinal pigmentosa symptoms, and the family did not exhibit any association with any other anomaly. Sanger sequencing was performed on one affected member of this family; the c.C75A, p.Asp25Glu mutation was found in RP-21 (Figure 1B), and segregation of the identified mutation was confirmed on remaining individuals (Figure 1A). Several bioinformatics tools were used to assess potential impact of variation. To analyze the conservation of amino acids the Clustal-W tool was used; aspartate is a highly conserved residue across various homologous species (Figure 1C). The c.C75A alteration was predicted using bioinformatics proficiency tools; all tools supported this transitory change. Polypehn2 scores a 1 for this change, indicating it is likely harmful, with a Provean score of -3.00 and mutation evidence supporting variation c.C75A as a disease-causing mutation. The phrye2 tool results show the wild and mutant protein changes in the CLCC1 gene (Figure 1D)

After a comprehensive clinical examination, the fundus examination of patients III-5 showed a mildly pigmented free zone in the distant periphery of both eyes and a minor spread of pigmentation in that same area (Figure 2A). The fundus of individuals III-6 showed large pigmentations in the far peripheral region of the right eye, whereas little pigmentations are present in the mild area; in the left eyesight of individuals III-6, the fundus contains mild pigmentation in the periphery region, a macular clear from pigmentation and a slight pigmentation in the vast periphery region were seen (Figure 2B). In individuals III-7, the pigmentation is apparent in the far peripheral area, and a mild left eye region was transparent from pigments. In contrast, in the right eye of individual III-7, the mild region of the fundus was clear from pigmentation, and the far peripheral region of the eye was foggy and condensed (Figure 2C). Optical coherence tomography (OCT), a diagnostic test, was performed to analyze the retinal thickness and the condition of the retinal pigment epithelial layer among the individuals. The OCT result of individual III-5 reveals that both eyes' retinal pigment epithelial layer was smoothly settled with retinal thickness measurements of both eyes 213  $\mu\text{m}$  and 220  $\mu\text{m}$ , and the standard average measurement was 269  $\mu\text{m}$  (Figure 2A). The OCT result for individuals III-6 indicated that both eyes were abnormally thick; the thickness values obtained for each eye were 245  $\mu\text{m}$  and 235  $\mu\text{m}$ , respectively, and the average thickness value was 228  $\mu\text{m}$  and retinal pigment epithelial layers were scattered in both eyes (Figure 2B). In individuals III-7, the retinal pigment layer was lightly settled. The OCT thickness value was recorded at 197 $\mu\text{m}$  and 214 $\mu\text{m}$  in both eyes of individuals III-7, and the typical average value of both eyes was 219 $\mu\text{m}$  (Figure 2C).

## DISCUSSION

Chloride channel CLIC-like protein 1 regulates cellular trafficking signals and plays an essential role in retinal structure. In addition, blockage of CLC Cl<sup>-</sup> channels in mice results in retinal degeneration (10). Cl<sup>-</sup> channels promote aberrant lysosomal trafficking function, which causes retinal degeneration by stimulating the ions inside the endosomal-lysosomal pathway's medium (10).

The association of CLCC1 to cause retinal degeneration disorder was firstly reported from Pakistan. A homozygous missense mutation c.75C>A, p.D25E of CLCC1 was found in seven consanguineous families of the Pakistani population and one British-Bangladeshi family. This mutation was associated with arRP, the p.Asp25Glu mutation reduced CLCC1 channel function. Additionally, mutant CLCC1 protein accumulated in granules within the endoplasmic reticulum (ER) lumen, suggesting a disruption in protein processing or trafficking (11).

The Knockdown of CLCC1 mRNA in cultured retinal pigment epithelium (RPE) cells induced apoptosis, identified the crucial role for CLCC1 in cell survival and TALEN knockout (KO) of CLCC1 in zebrafish resulted in lethality by eleven days post-fertilization. Zebrafish KO showed no satisfactory electroretinogram (ERG) cone and cone spectral sensitivity response, reduced eye size, retinal thickness, and expression of rod and cone opsins and Injection of wild-type CLCC1 mRNA rescued the phenotypic defects in zebrafish KO. Clcc1<sup>+/-</sup> KO mice showed abnormal ERGs result and photoreceptor numbers, the CLCC1 perform crucial role for maintaining retinal integrity and function. These findings indicate that intracellular chloride transport mediated by CLCC1 is participate for maintaining retinal integrity and function. CLCC1 is essential for the survival and function of normal retinal cells, highlighting its potential as a therapeutic target for arRP and possibly other retinal degenerative disorders (11).

The exon 1 of CLCC1 gene contains a substitution variation, c.C75A, which cause the missense variation p.Asp25Glu. The encoded protein of the CLCC1 gene is 551 amino acids long and comprises ten exons totalling 4.83 kilobases in size. According to data from the gnomAD database (<http://gnomad.broadinstitute.org/>), the allele frequency of the variant c.C75A, p.Asp25Glu, is 0.000056, indicating a very low frequency of the abovementioned variant ([https://gnomad.broadinstitute.org/gene/ENSG00000121940?dataset=gnomad\\_r4](https://gnomad.broadinstitute.org/gene/ENSG00000121940?dataset=gnomad_r4))(12).

Additionally, the CLCC1 gene's probability of LOF intolerance (PLI) was determined using the method, and the PLI score for CLCC1 was found to be 0.03. Furthermore, neither the HGMD nor the ExAC databases (<https://gnomad.broadinstitute.org/gene/ENSG00000121940?dataset=exac>) database. According to bioinformatics tools, the variation is likely pathogenic and responsible for protein abnormalities. Additionally, it was utterly segregated from the familial phenotype. For a better understanding of the activity of the CLCC1 gene in human eyes and the impact of its variations on the development of RP, in vitro and animal-based functional investigations are crucial.

The c.75C > A CLCC1 mutation is a moderately common cause of autosomal recessive retinitis pigmentosa (arRP) in the Pakistani population; it is essential to note that this figure reflects only a part of the genetic causes contributing to this condition in the Pakistan population. A thorough clinical examination revealed the typical symptoms of retinitis pigmentosa, typically present in people with RP with mutations in other genes. The condition usually manifests itself in the second decade of life. The youngest patient, III-5, had good vision and no complaints, but a fundus examination revealed mild pigmentation, which may indicate the beginning stages of RP.

According to the earlier study, sharing an identical single nucleotide polymorphism (SNP) haplotype among affected individuals from seven consanguineous families of Pakistan, as well as one British-Bangladeshi family indicated to a common ancestral mutation. The frequency estimation of 0.03, derived from the EM algorithm within the Golden Helix SVS program. Previously study further supports that British-Bangladeshi family sharing identical haplotype indicates that family probably of Punjabi Pakistani ancestor. The findings regarding the CLCC1 mutation in the Pakistani population offer valuable insights into its origin and transmission. The estimated timeframe of 2000–5,000 years ago suggests that this pathogenic variation emerged relatively recently in human history, possibly coinciding with significant historical background or population movements in the region (13). The fact that affected families of Pakistani descent are found in various regions globally highlights the dispersal of this genetic variant over time, likely through migration and intermarriage. Furthermore, the absence of further pathogenic variation in the CLCC1 gene shows a high degree of genetic conservation. This indicates that the CLCC1 gene highly involves in biological processes, such as embryonic development stage, where small change may have cause major effects. Deciphering the significance of this gene variation for human development and health necessitates an understanding of its functional requirements.

### CONCLUSION

This finding of a pathogenic allele in this family provides information to better understand the disease pattern at a molecular level, which can significantly aid in genetic counseling and the development of targeted treatments for affected patients. By identifying the specific mutations and their phenotypic effects, the consultant professionals can better guide the affected families in Pakistan. Additionally, this data contributes to understanding the allele frequency of the identified mutation, which is crucial for epidemiological studies and future research endeavors.

### ACKNOWLEDGEMENTS

The authors want to thank to all laboratory staff and the volunteers who participated in this research.

**Ethical permission:** Sindh Institute of Ophthalmology and visual Sciences IRB letter No. SIOVS/EXEC.DIR/7516.

**Conflict of Interest:** No conflicts of interest.

**Financial Disclosure / Grant Approval:** No funding agency was involved in this research.

**Data Sharing Statement:** The corresponding author can provide the data proving the findings of this study on request. Privacy or ethical restrictions bound us from sharing the data publicly.

### AUTHOR CONTRIBUTIONS

Yar Muhammad Waryah: Study design, collection of data and drafting,

Feriah Fatima Khidiri: Critical review

Amir Ansari: help in re- identification of family and review of article

Samia Mehmood: data analysis

Sumera Abbasi: help in clinical chemistry investigations

Shabahat Memon: help in clinical analysis



**REFERENCES**

1. Karali M, Testa F, Brunetti-Pierri R, Di Iorio V, Pizzo M, Melillo P, et al. Clinical and Genetic Analysis of a European Cohort with Pericentral Retinitis Pigmentosa. *International journal of molecular sciences*. 2019;21(1). Epub 2019/12/28.
2. Dawood M, Lin S, Din TU, Shah IU, Khan N, Jan A, et al. Novel mutations in PDE6A and CDHR1 cause retinitis pigmentosa in Pakistani families. *International journal of ophthalmology*. 2021;14(12):1843-51. Epub 2021/12/21.
3. Bruninx R, Lepièce G. [Retinitis pigmentosa]. *Revue medicale de Liege*. 2020;75(2):73-4. Epub 2020/02/08. L'image du mois. La rétinite pigmentaire.
4. Sen P, Bhargava A, George R, Ve Ramesh S, Hemamalini A, Prema R, et al. Prevalence of retinitis pigmentosa in South Indian population aged above 40 years. *Ophthalmic epidemiology*. 2008;15(4):279-81. Epub 2008/09/10.
5. Marwan M, Dawood M, Ullah M, Shah IU, Khan N, Hassan MT, et al. Unravelling the genetic basis of retinal dystrophies in Pakistani consanguineous families. *BMC ophthalmology*. 2023;23(1):023-02948.
6. Bhardwaj A, Yadav A, Yadav M, Tanwar M. Genetic dissection of non-syndromic retinitis pigmentosa. *Indian journal of ophthalmology*. 2022;70(7):2355-85. Epub 2022/07/07.
7. Verbakel SK, van Huet RAC, Boon CJF, den Hollander AI, Collin RWJ, Klaver CCW, et al. Non-syndromic retinitis pigmentosa. *Progress in retinal and eye research*. 2018;66:157-86. Epub 2018/03/30.
8. Grimberg J, Nawoschik S, Belluscio L, McKee R, Turck A, Eisenberg A. A simple and efficient non-organic procedure for the isolation of genomic DNA from blood. *Nucleic acids research*. 1989;17(20):8390. Epub 1989/10/25.
9. Jarwar P, Sheikh SA, Waryah YM, Ujjan IU, Riazuddin S, Waryah AM, et al. Biallelic Variants in EPHA2 Identified in Three Large Inbred Families with Early-Onset Cataract. *International journal of molecular sciences*. 2021;22(19). Epub 2021/10/14.
10. Tang L, Tang X, Zhao Q, Li Y, Bu Y, Liu Z, et al. Mutation and clinical analysis of the CLCC1 gene in amyotrophic lateral sclerosis patients from Central South China. *Annals of clinical and translational neurology*. 2024;11(1):79-88. Epub 2023/11/02.
11. Li L, Jiao X, D'Atri I, Ono F, Nelson R, Chan CC, et al. Mutation in the intracellular chloride channel CLCC1 associated with autosomal recessive retinitis pigmentosa. *PLoS genetics*. 2018;14(8):e1007504. Epub 2018/08/30.
12. Chen S, Francioli LC, Goodrich JK, Collins RL, Kanai M, Wang Q, et al. A genomic mutational constraint map using variation in 76,156 human genomes. *Nature*. 2024;625(7993):92-100.
13. Ma Y, Wang X, Shoshany N, Jiao X, Lee A, Ku G, et al. CLCC1 c. 75C>A Mutation in Pakistani Derived Retinitis Pigmentosa Families Likely Originated With a Single Founder Mutation 2,000-5,000 Years Ago. *Frontiers in genetics*. 2022;13:804924. Epub 2022/04/09.

Figure Legends:

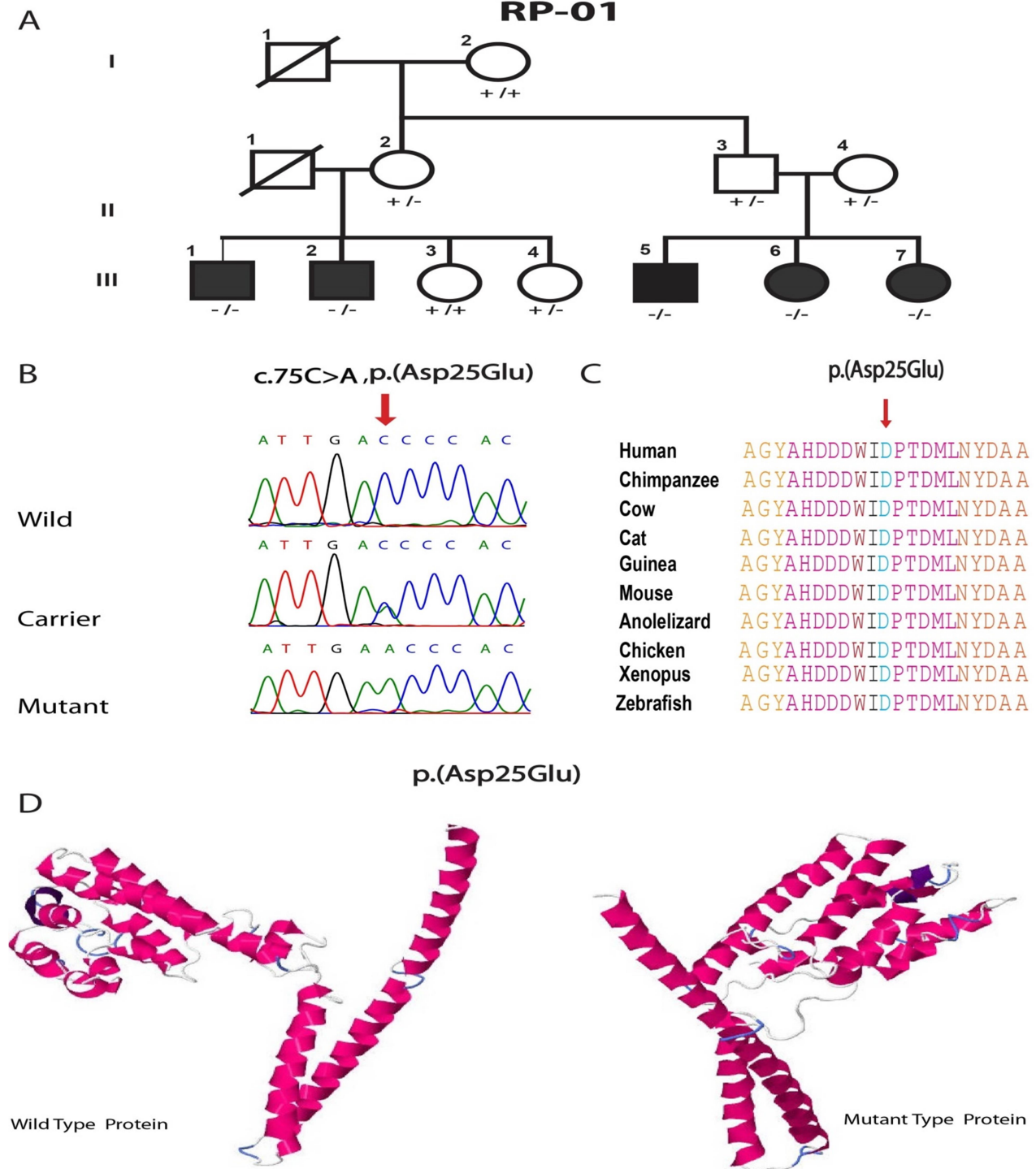


Figure I: (1A) showing the pedigree of RP-01 (1B) chromatogram results of c.C75A, p.Asp25Glu, (1C) Clustal-W results of different homologues species, (1D) Phyre2 results of wild and mutant protein of Asp25Glu.



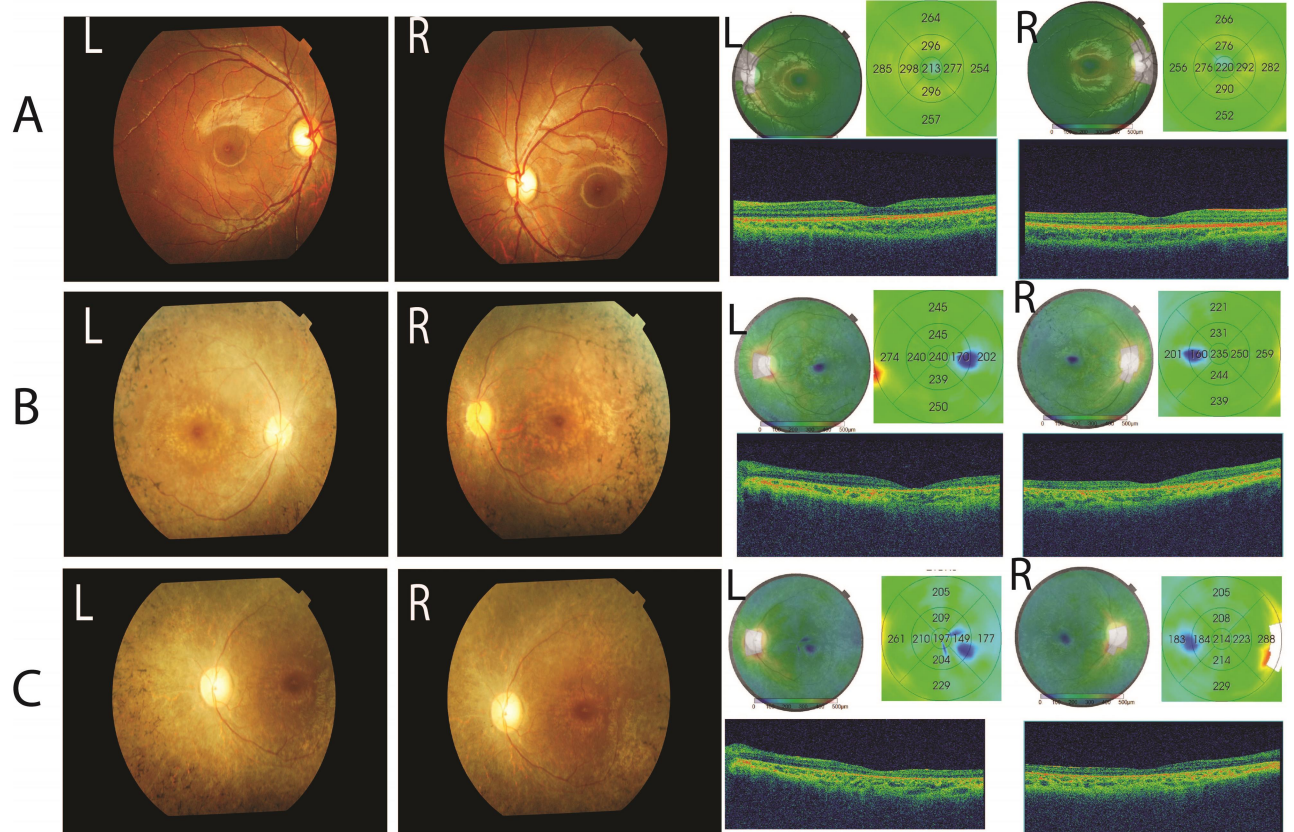


Figure II: (2A) fundus and OCT photographs of III-5, (2B) fundus and OCT photographs of III-6, (2C) fundus and OCT photographs of III-7